Pediatric Neurology 49 (2013) 243–254

Contents lists available at ScienceDirect

Pediatric Neurology

journal homepage: www.elsevier.com/locate/pnu

Original Article

Tuberous Sclerosis Complex Diagnostic Criteria Update: Recommendations of the 2012 International Tuberous Sclerosis Complex Consensus Conference

Hope Northrup MD [a,*], Darcy A. Krueger MD PhD [b], on behalf of the International Tuberous Sclerosis Complex Consensus Group

[a] *Division of Medical Genetics, Department of Pediatrics, University of Texas Medical School at Houston, Houston, Texas*
[b] *Division of Neurology, Department of Pediatrics, Cincinnati Children's Hospital Medical Center, University of Cincinnati College of Medicine, Cincinnati, Ohio*

ABSTRACT

BACKGROUND: Tuberous sclerosis complex is highly variable in clinical presentation and findings. Disease manifestations continue to develop over the lifetime of an affected individual. Accurate diagnosis is fundamental to implementation of appropriate medical surveillance and treatment. Although significant advances have been made in the past 15 years in the understanding and treatment of tuberous sclerosis complex, current clinical diagnostic criteria have not been critically evaluated or updated since the last clinical consensus conference in 1998. **METHODS:** The 2012 International Tuberous Sclerosis Complex Consensus Group, comprising 79 specialists from 14 countries, was organized into 12 subcommittees, each led by a clinician with advanced expertise in tuberous sclerosis complex and the relevant medical subspecialty. Each subcommittee focused on a specific disease area with important diagnostic implications and was charged with reviewing prevalence and specificity of disease-associated clinical findings and their impact on suspecting and confirming the diagnosis of tuberous sclerosis complex. **RESULTS:** Clinical features of tuberous sclerosis complex continue to be a principal means of diagnosis. Key changes compared with 1998 criteria are the new inclusion of genetic testing results and reducing diagnostic classes from three (possible, probable, and definite) to two (possible, definite). Additional minor changes to specific criterion were made for additional clarification and simplification. **CONCLUSIONS:** The 2012 International Tuberous Sclerosis Complex Diagnostic Criteria provide current, updated means using best available evidence to establish diagnosis of tuberous sclerosis complex in affected individuals.

Keywords: diagnostic criteria, clinical features, tuberous sclerosis

Pediatr Neurol 2013; 49: 243-254

© 2013 Elsevier Inc. Open access under CC BY-NC-ND license.

See related articles on pages 223 *and* 255.

Introduction

Tuberous sclerosis complex (TSC) was initially described approximately 150 years ago by von Recklinghausen in 1862.[1] TSC is an extremely variable disease that can affect virtually any organ in the body. The most common findings are benign tumors in the skin, brain, kidneys, lung, and heart that lead to organ dysfunction as the normal parenchyma is replaced by a variety of cell types.[2] Disease manifestations in different organ systems can vary widely between even closely related individuals and the protean nature of the condition can make clinical diagnosis challenging. TSC was underdiagnosed until the 1980s when individuals with less severe manifestations of the disease began to be recognized. Before the 1980s, incidence rates for TSC were quoted at between 1/100,000 and 1/200,000.[3,4] Recent studies estimate a frequency of 1/6000 to 1/10,000 live births and a population prevalence of around 1 in 20,000.[5,6] Although TSC was recognized to be a genetic disease more than 100 years ago,[7] the underlying molecular etiology was not unraveled until the discovery of the two causative genes, *TSC1* and *TSC2*.[8,9]

The second International Tuberous Sclerosis Complex Consensus Conference was held June 13-14, 2012, in Washington, DC. Seventy-nine experts (Appendix) from 14

Article History:
Received 9 July 2013; Accepted 1 August 2013

* Communications should be addressed to: Dr. Northrup; Division of Medical Genetics; Department of Pediatrics; The University of Texas Medical School at Houston; MSB 3.144B; Houston, TX 77030.
E-mail address: hope.northrup@uth.tmc.edu

0887-8994 © 2013 Elsevier Inc. Open access under CC BY-NC-ND license.
http://dx.doi.org/10.1016/j.pediatrneurol.2013.08.001

TABLE.
Updated diagnostic criteria for tuberous sclerosis complex 2012

A. Genetic diagnostic criteria

The identification of either a TSC1 or TSC2 pathogenic mutation in DNA from normal tissue is sufficient to make a definite diagnosis of tuberous sclerosis complex (TSC). A pathogenic mutation is defined as a mutation that clearly inactivates the function of the TSC1 or TSC2 proteins (e.g., out-of-frame indel or nonsense mutation), prevents protein synthesis (e.g., large genomic deletion), or is a missense mutation whose effect on protein function has been established by functional assessment (www.lovd.nl/TSC1, www.lovd/TSC2, and Hoogeveen-Westerveld et al., 2012 and 2013). Other TSC1 or TSC2 variants whose effect on function is less certain do not meet these criteria, and are not sufficient to make a definite diagnosis of TSC. Note that 10% to 25% of TSC patients have no mutation identified by conventional genetic testing, and a normal result does not exclude TSC, or have any effect on the use of clinical diagnostic criteria to diagnose TSC.

B. Clinical diagnostic criteria

Major features

1. Hypomelanotic macules (≥3, at least 5-mm diameter)
2. Angiofibromas (≥3) or fibrous cephalic plaque
3. Ungual fibromas (≥2)
4. Shagreen patch
5. Multiple retinal hamartomas
6. Cortical dysplasias*
7. Subependymal nodules
8. Subependymal giant cell astrocytoma
9. Cardiac rhabdomyoma
10. Lymphangioleiomyomatosis (LAM)†
11. Angiomyolipomas (≥2)†

Minor features

1. "Confetti" skin lesions
2. Dental enamel pits (>3)
3. Intraoral fibromas (≥2)
4. Retinal achromic patch
5. Multiple renal cysts
6. Nonrenal hamartomas

Definite diagnosis: Two major features or one major feature with ≥2 minor features

Possible diagnosis: Either one major feature or ≥2 minor features

* Includes tubers and cerebral white matter radial migration lines.

† A combination of the two major clinical features (LAM and angiomyolipomas) without other features does not meet criteria for a definite diagnosis.

countries convened to finalize diagnostic, surveillance, and management recommendations for patients with TSC. A summary report of the current, updated surveillance and management recommendations for the standardized, optimal clinical management of patients with TSC is provided separately.[10] One of the major goals of the conference was to revisit the clinical diagnostic criteria published subsequent to the first International TSC Consensus Conference in 1998.[11] Since 1998, one additional manuscript regarding the diagnostic criteria has been published that was designed to provide more guidance to practitioners by including pictures of the major and minor findings.[12] At the 2012 meeting, the most significant change recommended to the diagnostic criteria was the incorporation of genetic testing. Although the *TSC1* and *TSC2* genes were discovered before the 1998 conference, molecular testing was not widely available at that time. Molecular testing of the *TSC1* and *TSC2* genes yields a positive mutation result for 75-90% of TSC-affected individuals categorized as "definite" by the 1998 Consensus Conference Clinical Diagnostic Criteria.[2] The use of molecular testing in medicine has expanded greatly since the 1990s, becoming widely accepted as invaluable in the diagnosis of diseases with a genetic basis. Utilization of genetic testing for TSC was addressed along with refinement of clinical criteria.

Genetic diagnostic criteria

Comprehensive and reliable screens for *TSC1* and *TSC2* mutations are well-established, and many pathogenic mutations have been identified (www.lovd.nl/TSC1, www.lovd/TSC2). The recommendation of the Genetics Panel was to make identification of a pathogenic mutation in *TSC1* or *TSC2* an independent diagnostic criterion, sufficient for the diagnosis or prediction of TSC regardless of the clinical findings (Table part A). This will facilitate the diagnosis of TSC in some, particularly young individuals, allowing earlier implementation of surveillance and treatment with potential for better clinical outcomes. A "pathogenic" mutation was defined as a mutation that clearly prevents protein synthesis and/or inactivates the function of the TSC1 or TSC2 proteins (e.g., nonsense mutation or frameshift mutations, large genomic deletions) or is a missense mutation whose effect on protein function has been established by functional assessment.[13,14] *TSC1* and *TSC2* genetic variants whose functional effect is less certain are not definitely pathogenic and would not be considered a major diagnostic criterion. A significant fraction (10-25%) of TSC patients have no mutation identified by conventional genetic testing. Therefore, a normal result does not exclude TSC. Nonetheless, if the mutation in an affected relative is known, testing for that mutation has very high predictive value for family members. Assembled experts at the Consensus Conference agreed with the recommendation that identification of a pathogenic mutation in *TSC1* or *TSC2* is an independent diagnostic criterion.

Clinical diagnostic criteria

In addition to diagnosis by genetic analysis, the clinical diagnostic criteria used to establish the diagnosis of TSC were also reviewed at the conference. Special attention was

FIGURE 1.
Three hypopigmented macules the lower back/upper buttocks.

given to evaluate the sensitivity and specificity of clinical findings with respect to TSC diagnosis. Panels were assigned to the following focus areas for this process, and specific attempts were made to refine and simplify the clinical diagnostic criteria that included 11 major features and nine minor features according to the 1998 Conference. The individual panels were organized as follows: (1) dermatology and dentistry; (2) ophthalmology; (3) brain structure, tubers, and tumors; (4) epilepsy; (5) TSC-associated neuropsychiatric disorders; (6) cardiology; (7) pulmonology; (8) nephrology; (9) endocrinology; (10) gastroenterology; and (11) care integration. The recommendations of each panel were presented to the entire congress for discussion, modification if necessary, and final approval. The new, updated diagnostic clinical criteria now include 11 major features and six minor features (Table part B).

Dermatologic and dental features

The dermatology and dental panel recommended retaining the existing mucocutaneous criteria and suggested minor changes regarding their number, size, or nomenclature. The major features (with changes italicized) include: (1) hypomelanotic macules (≥3, *at least 5-mm diameter*), (2) angiofibromas (≥3) or *fibrous cephalic* plaque, (3) ungual fibromas (≥2), and (4) shagreen patch. The revised minor features include: (1) "confetti" skin lesions, (2) dental enamel pits (≥3), and (3) *intraoral* fibromas (≥2). Nearly 100% of individuals affected with TSC have skin or dental findings of the disease that are easily detectable on physical examination. It is therefore important that these features be highlighted to aid in bringing TSC patients to medical attention.

FIGURE 2.
Facial angiofibromas.

Hypomelanotic macules

Hypomelanotic macules are a significant feature because they are observed in about 90% of individuals with TSC, they typically appear at birth or infancy, and they may be a presenting sign of TSC (Fig 1).[15-21] At the 1998 Consensus, it was stipulated that an individual must have three or more hypopigmented macules, because one or two lesions are relatively common in the general population.[22,23] In the updated criteria, it was recommended that hypomelanotic macules meet a size requirement of at least 5-mm diameter to distinguish hypomelanotic macules from smaller and more numerous "confetti" lesions. In addition, it was suggested that poliosis, circumscribed areas of hypomelanosis of hair, be included in the count of hypomelanotic macules.

Angiofibromas or fibrous cephalic plaque

Facial angiofibromas occur in about 75% of TSC patients (Fig 2),[15,16,18,21] with onset typically between ages 2 and 5 years.[24] Although most TSC patients have several facial angiofibromas, milder cases of TSC with limited facial angiofibromas have been described. However, because one or two isolated sporadic lesions may be observed in the general population,[25] the presence of at least three facial angiofibroma lesions is now recommended to meet this major criteria for TSC. Multiple facial angiofibromas have also been observed in Birt-Hogg-Dubé (BHD) syndrome, and multiple endocrine neoplasia type 1 (MEN1).[26,27] In these conditions, the age of onset of angiofibromas is later than in TSC. Therefore, multiple facial angiofibromas remains a major feature for diagnosis when their onset occurs in childhood. In the unusual circumstance when angiofibromas have their onset in adulthood, they should be considered as a minor feature and the differential diagnosis expanded to include BHD and MEN1. When angiofibromas are few or later in onset, a skin biopsy may be required to confirm the clinical diagnosis.

The forehead plaque is observed in about 25% of TSC patients and this feature was paired with angiofibromas for the diagnostic criteria in 1998 (Fig 3A). The panel recommended changing the terminology from forehead plaque to fibrous cephalic plaque. This term was created to increase awareness that these fibrous plaques, although often located unilaterally on the forehead, may occur on other parts of the face or scalp (Fig 3B). Fibrous cephalic plaques, which are histologically similar to angiofibromas, may be the most specific skin finding for TSC.

Ungual fibromas

Ungual fibromas were retained as a major feature (Fig 4). The previous designation as "nontraumatic" was eliminated because recall of trauma may be unreliable and trauma may play a role in the formation of TSC ungual fibromas.[28] This designation was replaced with the requirement that they be

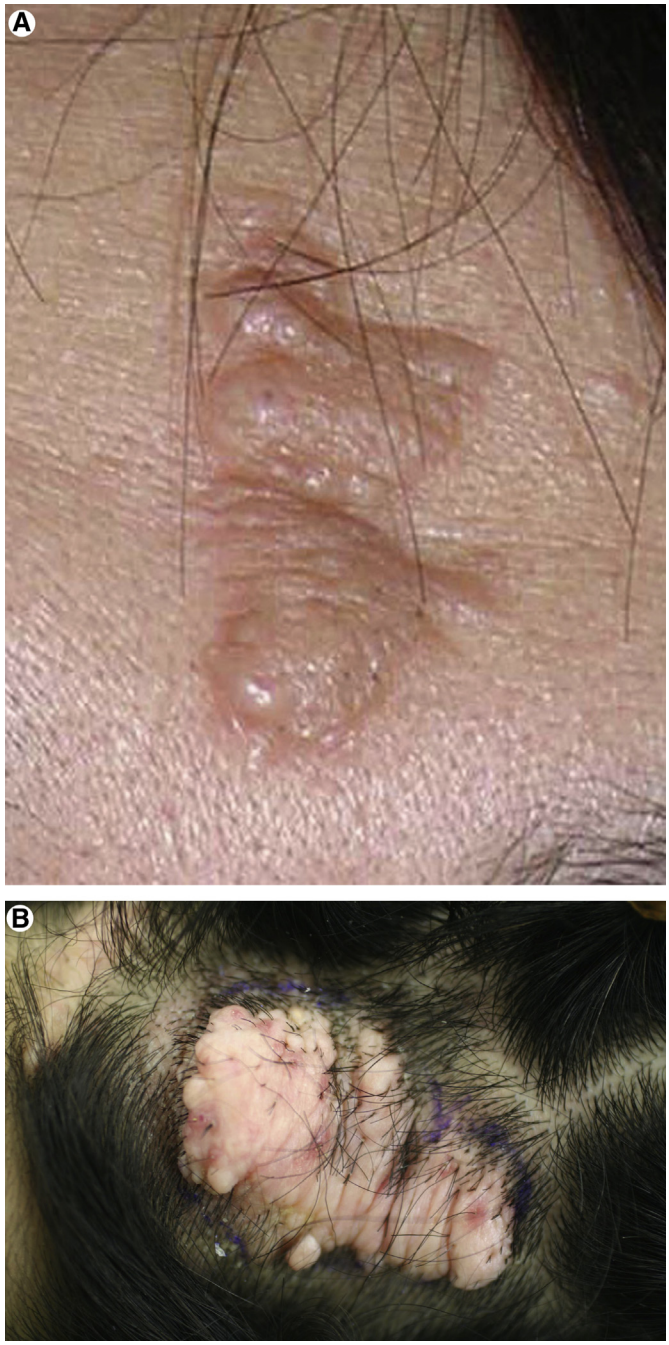

FIGURE 3.
(A) Fibrous plaque on face. (B) Fibrous plaque on scalp.

multiple (≥2) because ungual fibromas that occur in the general population in response to trauma are usually solitary.[29] The redundant phrase "ungual and periungual fibromas" was replaced with "ungual fibromas" used to encompass both periungual and subungual fibromas. Ungual fibromas are less common than some of the other TSC skin findings, with a frequency of about 20% overall but as high as 80% in older adults.[15,16,28] The greater frequency in adults is due to later onset, typically in the second decade or later.[18,21] Therefore, their utility in diagnosis is usually limited to adolescents and adults.[24]

FIGURE 4.
Ungual fibromas.

Shagreen patch

The presence of a shagreen patch was retained as a major feature, but the criterion was updated by deletion of "connective tissue nevus" because this term encompasses a variety of skin lesions with excessive dermal connective tissue that are not necessarily associated with TSC. Shagreen patches commonly take the form of large plaques on the lower back that have a bumpy or orange-peel surface, and this clinical appearance is nearly always specific for TSC (Fig 5). Smaller collagenomas on the trunk exhibit the same histologic changes as shagreen patches but are less specific for TSC because they may also occur as an isolated finding or in other genetic syndromes including MEN1,[26] BHD,[30] and Cowden syndrome.[31] Shagreen patches are observed in about 50% of individuals with TSC and typically have their onset in the first decade of life.[15,16,18,21]

"Confetti" skin lesions

Confetti skin lesions are numerous 1- to 3-mm hypopigmented macules scattered over regions of the body such as the arms and legs.[31] Their frequency varies widely in different studies, from 3% in children to about 58% overall.[15,24] Despite their relatively low frequency, confetti lesions may still be useful for diagnosis and they were retained as a minor feature. Their utility in adults is limited by the fact that many adults in the general population develop similar-appearing lesions as a consequence of chronic sun exposure. In such cases, the diagnosis of confetti lesions may be supported by a history of onset in

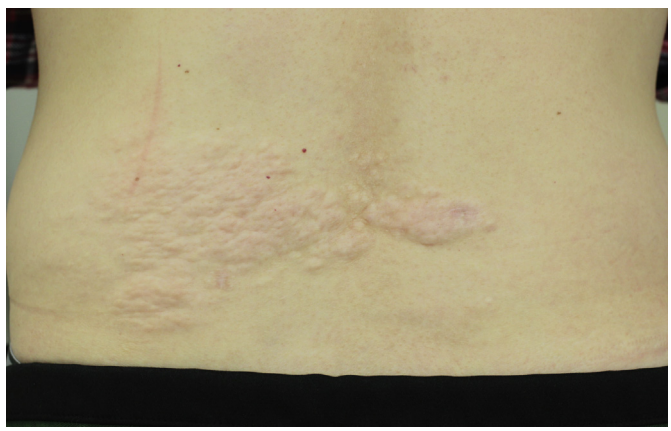

FIGURE 5.
Shagreen patch on dorsolumbar area of back.

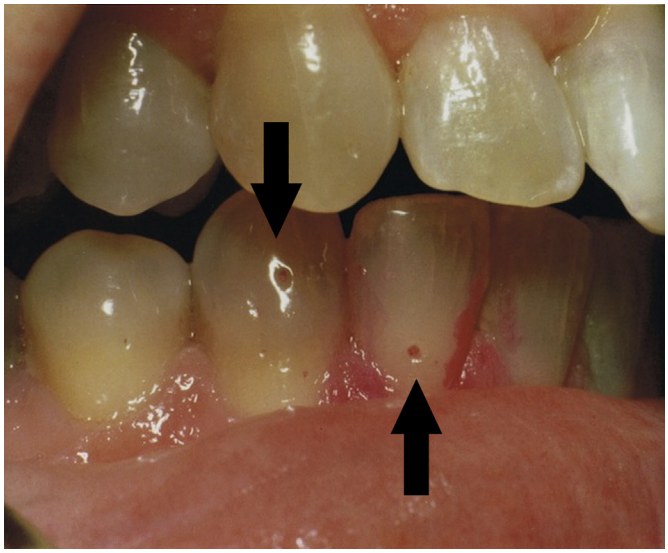

FIGURE 6.
Dental pits indicated by arrows.

the first decade of life or by asymmetric involvement of one body region over another.

Dental enamel pits

Dental enamel pits, previously included as a minor feature listed as "multiple, randomly distributed pits in dental enamel" were again included as a minor feature (Fig 6). The designation was simplified to dental enamel pits (≥3) for the entire dentition. Dental pits are much more common in TSC patients than the general population, with Mlynarczyk reporting 100% of adult TSC patients (n = 50) as having pitting compared with 7% of 250 adult control subjects.[32] Because they are relatively common in the population, they are listed as a minor feature.

Intraoral fibromas

Gingival fibromas have long been associated with TSC and were listed as a minor feature in the 1998 consensus document (Fig 7). They occur in about 20-50% of individuals with TSC, with greater frequency in adults than children.[15,21,33,34]

FIGURE 7.
Intraoral fibromas (gingival and labial indicated by arrows).

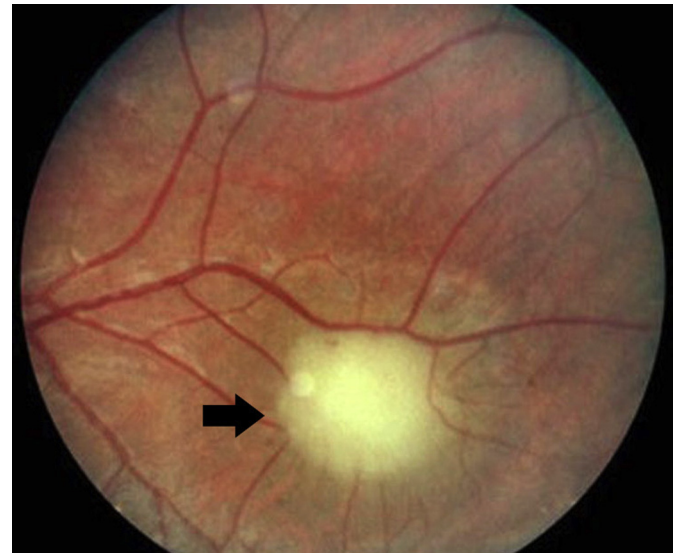

FIGURE 8.
Retinal hamartoma indicated by arrow.

Fibromas in TSC may also be observed on the buccal or labial mucosa and even the tongue,[34] so this criterion was modified to include fibromas at other intraoral sites. A stipulation was added for the presence of two or more intraoral fibromas because solitary oral fibromas may occur in the general population, particularly on the tongue or buccal mucosa along the bite line from repeated trauma.[35,36]

Bone cysts

Bone cysts were included in the 1998 criteria as a minor feature of TSC. Because of the lack of specificity for TSC and because the feature is rarely identified in the absence of additional TSC clinical features, a decision was made to delete "bone cysts" from the clinical diagnostic criteria.

Ophthalmologic features

Multiple retinal hamartomas

The finding of more than one retinal hamartoma was determined to be significant and specific enough to retain as a major feature (Fig 8). These lesions have similar histologic features to the tubers located in the brains of TSC patients. They are observed in 30-50% of TSC patients and it is not unusual to have multiple lesions in the same patient.[37,38] The prevalence of retinal hamartomas in non-TSC populations is not known, but rare case reports have been made and a recent series of 3573 healthy term newborns identified only two cases of astrocytic hamartomas in that population.[39] Fortunately, these lesions in TSC usually do not cause problems with vision and are a good marker for the disease, particularly in young children who might not yet have many other features.

Retinal achromic patch

The presence of a retinal achromic patch was determined at the 1998 conference to constitute a minor feature (Fig 9). The assembled experts at the 2012 conference concurred with the previous recommendation. Retinal achromic patches are basically areas of hypopigmentation on the retina. These patches have been noted to occur in 39% of TSC

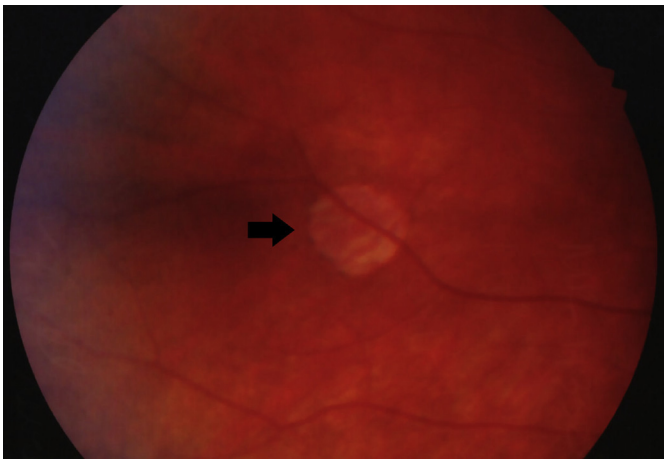

FIGURE 9.
Retinal achromic patch indicated by arrow.

patients.[38,40] Incidence in the general population is estimated at 1 in 20,000.[41]

Central nervous system features

Because medical problems relating to the brain result in the greatest morbidity and mortality in TSC, three panels at the 2012 Consensus Conference devoted their efforts to central nervous system–related findings of TSC. The panels were: (3) brain structure, tubers, and tumors; (4) epilepsy; and (5) TSC-associated neuropsychiatric disorders. The three panels were in agreement that there should be three neurological findings categorized as major features and that the minor feature of cerebral white matter radial migration lines should be subsumed into one of the major features as reviewed in the following sections. Thus, findings relating to the central nervous were streamlined.

Cortical dysplasias

Cortical dysplasias are congenital abnormalities caused, at least in part, when a group of neurons fail to migrate to the proper area of the brain during development. The cortical tubers observed in ~90% of TSC patients and the pathologic finding for which the disorder is named, are a type of focal cortical dysplasia. Cerebral white matter radial migration lines arise from a similar pathologic process as cortical tubers and other forms of cortical dysplasia and in TSC it is not unusual to find tubers and white matter migrational abnormalities together (Fig 10A). Both types of cortical dysplasia in TSC are commonly associated with intractable epilepsy and learning difficulties in TSC. The pathologic and clinical overlap between "cortical tuber" as a major feature and "cerebral white matter radial migration lines" as a minor feature in the 1998 diagnostic criteria were felt to no longer represent separate processes and are replaced with a single major feature in the new classification "cortical dysplasia." However, it is appreciated that a single area of focal cortical dysplasia or even two can be observed in an individual who does not have TSC; thus, in the new diagnostic criteria, multiple areas of focal cortical dysplasia count only as one major feature and additional clinical features are necessary to establish a definite diagnosis of TSC.

Subependymal nodules and subependymal giant cell astrocytomas

Subependymal nodules (SEN) and subependymal giant cell astrocytoma (SEGA) will continue to represent two separate major features (Fig 10B). Both of these lesions were also included in the 1998 Consensus Conference Criteria as major features. Histologically, the two lesions are similar and both are relatively specific to TSC although not exclusive to the disorder. Subependymal nodules are benign growths that develop along the wall of the ependymal lining of the lateral and third ventricles. They are observed in 80% of TSC patients and often prenatally detected or at birth.[42] SEGAs

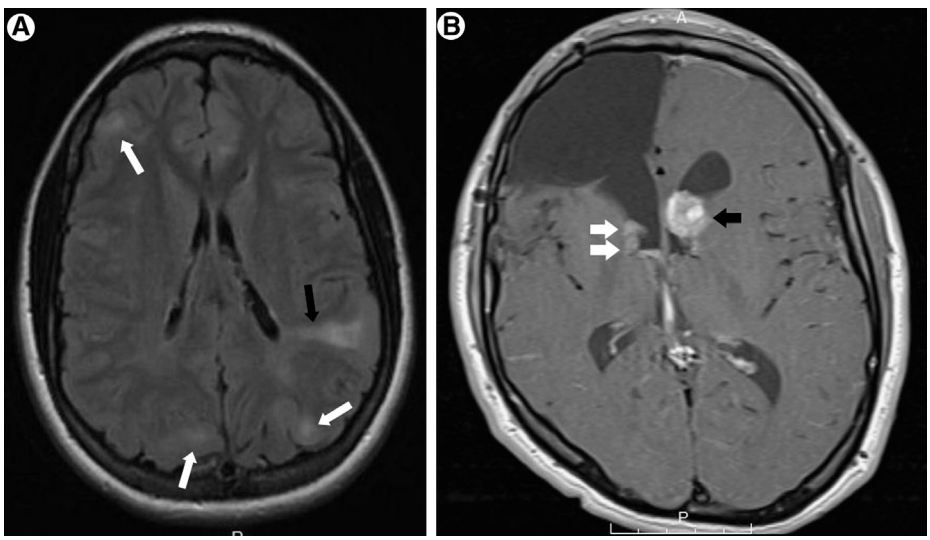

FIGURE 10.
(A) Axial magnetic resonance imaging (MRI) (T2 fluid-attenuated inversion recovery) of the brain, demonstrating cortical dysplasia (tubers and radial migration lines indicated by white and black arrows, respectively). (B) Axial MRI (T1 + contrast) of the brain, demonstrating subependymal nodules (left, two white arrows) and subependymal giant cell astrocytoma (right, black arrow). This patient also has undergone previous partial frontal lobectomy for epilepsy.

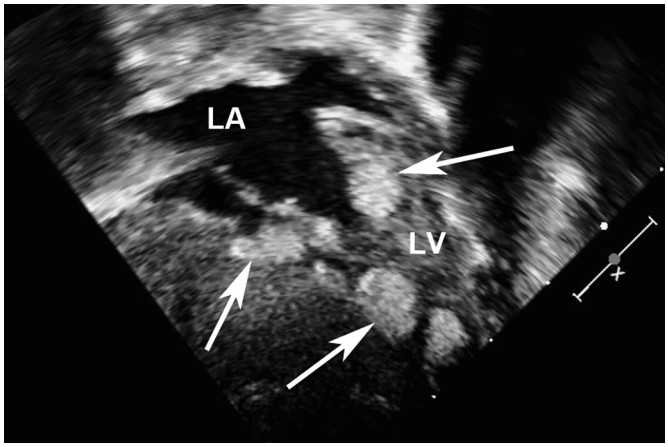

FIGURE 11.
Echocardiogram indicating cardiac rhabdomyomas (arrows).

have an incidence of 5-15% in TSC and may also be detected prenatally or at birth, although they are much more likely to arise during childhood or adolescence and it would be unusual for one to occur after the age of 20 years if not already previously present.[42] It is widely accepted that SEGAs typically arise from SEN, especially near the foramen of Monro. Although benign and typically slow-growing, they can cause serious neurologic compromise including obstructive hydrocephalus. Both SENs and SEGAs may progressively calcify over time.[42]

Cardiovascular features

The cardiology panel recommended retaining "cardiac rhabdomyoma" as a major feature and determined that there is no need to specify one versus more than one.

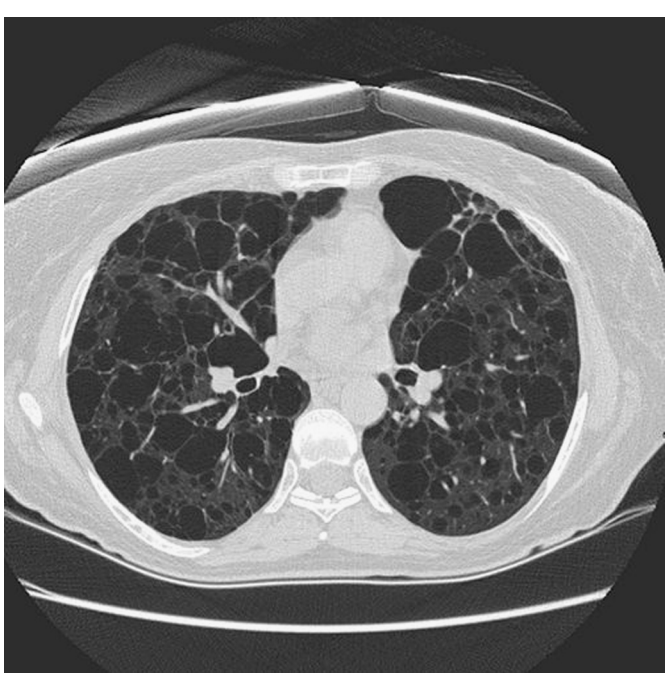

FIGURE 12.
Axial high-resolution chest computed tomography, demonstrating lymphangioleiomyomatosis.

Cardiac rhabdomyoma

Cardiac rhabdomyomas are benign tumors of the heart that are rarely observed in non-TSC–affected individuals (Fig 11). These lesions usually do not cause serious medical problems, but they are highly specific to TSC and often the first noted manifestation of disease, and therefore remain a major feature. Tumors are most frequently located in the ventricles, where they can compromise ventricular function and on occasion interfere with valve function or result in outflow obstruction.[43] These tumors are frequently observed in TSC-affected individuals during fetal life but after birth, they often regress and in some individuals may no longer be detectable by echocardiographic examination.[44,45] They are associated with cardiac arrhythmias including atrial and ventricular arrhythmia and the Wolff-Parkinson-White syndrome.

The prenatal presence of a cardiac rhabdomyoma is associated with a 75-80% risk of TSC, with multiple rhabdomyomas conveying an even higher risk.[46-48] Further, in the era preceding genetic testing, there was a <0.1% occurrence of cardiac rhabdomyoma in individuals not affected with TSC. Because they are frequently observed in fetal life, unlike other findings in TSC, they are important in bringing the patient to medical attention early in life. At that point, new interventions may be more likely to improve prognosis.

Pulmonary features

The pulmonology panel recommended retaining the finding of lymphangioleiomyomatosis (LAM) as a major feature of the clinical criteria to diagnose TSC. The other experts agreed with this recommendation.

Lymphangioleiomyomatosis

Histologically, LAM is associated with interstitial expansion of the lung with benign-appearing smooth muscle cells that infiltrate all lung structures.[49,50] Patients typically present with progressive dyspnea on exertion and recurrent pneumothoraces in the third to fourth decade of life. Cystic pulmonary parenchymal changes consistent with LAM are observed in 30-40% of female TSC patients (Fig 12), but recent studies suggest that lung involvement may increase with age such that up to 80% of TSC females are affected by age 40.[51] Cystic changes consistent with LAM are also observed in about 10-12% of males with TSC, but symptomatic LAM in males is very rare.[52,53] It is important to note that lung is rarely biopsied in TSC patients with pulmonary parenchymal changes, so it is possible that processes other than LAM may result in cystic lung disease in TSC patients. LAM is also diagnosed in individuals who do not have TSC, and is referred to as sporadic LAM (S-LAM).[49] In these patients, LAM is thought to occur through two somatic mutations in the *TSC2* gene, rather than through a germ line mutation and a "second-hit" somatic mutation that is typical for TSC.[54] That about one third of S-LAM patients have renal angiomyolipomas, another major feature in the diagnostic criteria for TSC, led to the conclusion by the 1998 consensus group that when both angiomyolipoma and LAM were present, other TSC features must be present for the diagnosis of TSC (status per current Consensus Conference discussed in next section). The

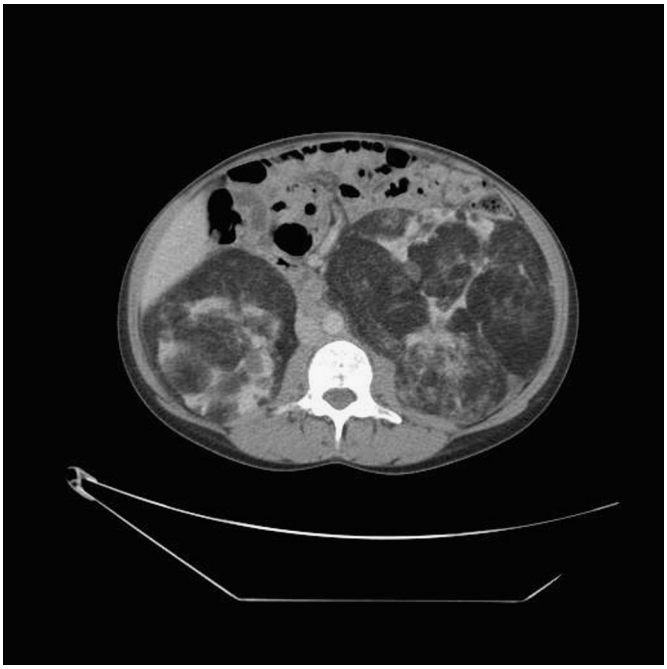

FIGURE 13.
Axial abdominal computed tomography, illustrating multiple bilateral renal angiomyolipomata. The darker areas are fat containing angiomyolipomatous tissue.

members of the pulmonology panel agreed with the principle that TSC diagnostic criteria must clearly differentiate S-LAM from TSC-LAM, and suggested the following modified language: "When angiomyolipomas and LAM are both present in a patient with suspected TSC, together they constitute only one major criterion."

The diagnosis of LAM as defined by the pulmonology panel is: (1) pathologic examination consistent with LAM, (2) characteristic as defined by the European Respiratory Society (ERS) criteria high-resolution chest computed tomography (HRCT) with profusion of cysts (>4) and no confounding comorbid conditions or exposures in a patient with at least one other major criteria for TSC (other than angiomyolipoma), or two other minor criteria, *OR* (3) characteristic or compatible (ERS criteria) HRCT in the setting of no confounding comorbid conditions or exposures, plus one of the following: abdominal or thoracic lymphangioleiomyomas, chylous pleural effusion, or chylous ascites.[49]

Other manifestations of tuberous sclerosis in the lung include multifocal micronodular pneumocyte hyperplasia (MMPH) and clear cell tumor of the lung. In MMPH, multiple pulmonary nodules composed of benign alveolar type II cells are found scattered throughout the lung. These lesions stain with cytokeratin and surfactant proteins A and B, but not with HMB-45, alpha smooth muscle actin, or hormonal receptors.[55] MMPH does not have known prognostic or physiologic consequences, although there have been at least two reports of respiratory failure associated with MMPH.[55,56] The precise prevalence of MMPH in patients with TSC is not known, but may be as high as 40-58%.[57,58] There is no gender restriction and MMPH may occur in the presence or absence of LAM in patients with TSC.[58] MMPH can be confused with atypical adenomatous hyperplasia, which is premalignant lesion that is not clearly associated with TSC. Clear cell tumor of the lung (CCSTL) is a rare and typically benign mesenchymal tumor composed of histologically and immunohistochemically distinctive perivascular epithelioid cells. Together LAM, angiomyolipoma, and CCSTL constitute the major members of the PEComa family of lung tumors.[59] The members of the pulmonary subcommittee did not feel that the specificity of MMPH and CCSTL for TSC have been established with sufficient clarity to suggest their inclusion as diagnostic criteria.

Renal features

The nephrology panel attending the Consensus Conference agreed with deleting the designation of "renal" in the major feature "renal angiomyolipomas" to now use "angiomyolipomas ≥2" in the clinical diagnostic criteria. Angiomyolipomas have been identified in TSC patients in organs other than the kidney including the liver.[60] As a result, "angiomyolipomas (≥2)" was added to the major features. The nephrology panel recommended not using the abbreviation "AMLs" for angiomyolipomas. Although this abbreviation has been commonly used among individuals familiar with TSC, in most medical contexts it is more familiarly associated with acute myelocytic leukemia and thus introduces confusion across specialties. The nephrology panel also recommended retaining "multiple renal cysts" as a minor feature. This recommendation was accepted by the other panelists. Additionally, it was agreed that an individual who has LAM and renal angiomyolipomas but no other features of TSC does not meet criteria for a definite diagnosis because of the previously reviewed information regarding S-LAM.

Renal manifestations in TSC are an important source of morbidity and mortality. In the only publication assessing mortality associated with TSC,[61] renal problems in TSC were the second leading cause of premature death after severe intellectual disability. With advances in medical care, death in TSC from renal disease is much less likely; however, it continues to represent a significant medical burden to TSC patients.

Angiomyolipomas

Angiomyolipomas are benign tumors composed of vascular, smooth muscle, and adipose tissue (Fig 13).[62] These benign tumors are observed most commonly in TSC patients in the kidney but can occur in other organs. To be inclusive of angiomyolipomas in other organs, it was decided to delete "renal" and simply use the term "angiomyolipomas (N ≥ 2)" as a major recognized feature. Angiomyolipomas are a feature relatively specific to TSC. Fat-containing angiomyolipomas were observed in 80% of TSC patients, and fat-poor lesions are also common in patients with TSC, but occur in less than 0.1% of the general population.[63] Angiomyolipomas in the kidney can cause serious issues with bleeding because of its vascular nature and can lead to need for dialysis and even renal transplantation.[64]

Multiple renal cysts

Multiple renal cysts are not commonly observed in the general population,[65] but can be seen in TSC patients who

have a *TSC1* or *TSC2* mutation or as part of a contiguous gene deletion syndrome involving the *TSC2* and *PKD1* genes.[62] The *TSC2* and *PKD1* genes are immediately adjacent and transcribed in opposite directions on chromosome 16p13.3. Deletions involving both genes have been described in a small subset of TSC patients who have the TSC phenotype as well as an aggressive PKD phenotype.[66] Presence of multiple simple renal cysts in older individuals in the general population is well-described, thus the decision was made to specify multiple renal cysts and relegate this feature to the minor status. In cross-sectional studies the number of cysts in healthy people vary with age and standards have been derived to help diagnose specific cystic disease states.

Endocrine features

Limited findings of TSC have been reported in the endocrine system. Various kinds of hamartoma do occur in the endocrine system.[67] According to early reports, adrenal angiomyolipoma can be present in a quarter of TSC patients, but rarely, if ever, causes hemorrhage.[68-70] Thyroid papillary adenoma have been reported in TSC patients,[71,72] but did not cause thyroid dysfunction. There are rare case reports of other angiomyolipoma or fibroadenoma in the pituitary gland, pancreas, or gonads.[67] These tumors are considered as representing minor features under the designation "nonrenal hamartomas." The recommendation was made by the endocrinology panel to retain nonrenal hamartomas as a minor feature to include these findings in the endocrine system of TSC-affected individuals. It was speculated that neuroendocrine tumors might be slightly more prevalent in TSC patients.[67,73] However, neuroendocrine tumors are not hamartomas and are not considered part of the diagnostic criteria.

Gastrointestinal features

Similarly, gastrointestinal manifestations in TSC patients are fairly rare. Liver angiomyolipomas are reported in 10-25% of TSC patients,[74] and these lesions are included in the major features group under the heading "Angiomyolipomas" (discussed previously). Hamartomatous rectal polyps were included as a minor feature in the 1998 Diagnostic Criteria. It was decided because of the lack of specificity for TSC and because they are another type of "nonrenal hamartoma" that the specific designation of "hamartomatous rectal polyps" would be deleted from the minor criteria.

Acknowledgments

The 2012 International TSC Clinical Consensus Conference was sponsored and organized by the Tuberous Sclerosis Alliance. The conference was supported by generous sponsors who donated funds to the Tuberous Sclerosis Alliance without playing a role in the planning or having a presence at the conference or any influence on the resulting recommendations: the Rothberg Institute for Childhood Diseases, Novartis Pharmaceuticals, Sandra and Brian O'Brien, and Questcor Pharmaceuticals.

References

1. von Recklinghausen F. *Die Lymphelfasse und ihre Beziehung zum Bindegewebe [German]*. Berlin: A. Hirschwald; 1862.
2. Northrup H, Koenig M, Au K. Tuberous sclerosis complex. *GeneReviews*. 2011; http://www.genetests.org.
3. Stevenson A, Fischer O. Frequency of epiloia in Northern Ireland. *Br J Prev Soc Med*. 1956;10:134-135.
4. Nevin N, Pearse W. Diagnostic and genetical aspects of tuberous sclerosis. *J Med Genet*. 1968;5:273-280.
5. O'Callaghan F, Shiell A, Osborne J, Martyn C. Prevalence of tuberous sclerosis estimated by capture-recapture analysis. *Lancet*. 1998;352:318-319.
6. Sampson J, Scahill S, Stephenson J, Mann L, Connor J. Genetic aspects of tuberous sclerosis in the west of Scotland. *J Med Genet*. 1989;26:28-31.
7. Kirpicznik J. Ein Fall von Tuberoser Sklerose and gleichzeitigen multiplem Nierengeschwülstein. *Virchows Arch Pathol Anat*. 1910;202:358.
8. European Chromosome 16 Tuberous Sclerosis Consortium. Identification and characterization of the tuberous sclerosis gene on chromosome 16. *Cell*. 1993;75:1305-1315.
9. van Slegtenhorst M, deHoogt R, Hermans C, et al. Identification of the tuberous sclerosis gene TSC1 on chromosome 9q34. *Science*. 1997;277:805-808.
10. Krueger DA, Northrup H, The International Tuberous Sclerosis Complex Consensus Group. Tuberous Sclerosis Complex Surveillance and Management: Recommendations of the 2012 International Tuberous Sclerosis Complex Consensus Conference. *Pediatr Neurol*. 2013;49:255-265.
11. Roach E, Gomez M, Northrup H. Tuberous sclerosis complex consensus conference: revised clinical diagnostic criteria. *J Child Neurol*. 1998;13:624-628.
12. Roach ES, Sparagana SP. Diagnosis of tuberous sclerosis complex. *J Child Neurol*. 2004;19:643-649.
13. Hoogeveen-Westerveld M, Ekong R, Povey S, et al. Functional assessment of TSC2 variants identified in individuals with tuberous sclerosis complex. *Hum Mutat*. 2013;34:167-175.
14. Hoogeveen-Westerveld M, Ekong R, Povey S, et al. Functional assessment of TSC1 missense variants identified in individuals with tuberous sclerosis complex. *Hum Mutat*. 2012;33:476-479.
15. Au K, Williams A, Roach E, et al. Genotype/phenotype correlation in 325 individuals referred for a diagnosis of tuberous sclerosis complex in the United States. *Genet Med*. 2007;9:88-1000.
16. Dabora SL, Jozwiak S, Franz DN, et al. Mutational analysis in a cohort of 224 tuberous sclerosis patients indicates increased severity of TSC2, compared with TSC1, disease in multiple organs. *Am J Hum Genet*. 2001;68:64-80.
17. Datta AN, Hahn CD, Sahin M. Clinical presentation and diagnosis of tuberous sclerosis complex in infancy. *J Child Neurol*. 2008;23:268-273.
18. Jozwiak S, Schwartz RA, Janniger CK, Michalowicz R, Chmielik J. Skin lesions in children with tuberous sclerosis complex: their prevalence, natural course, and diagnostic significance. *Int J Dermatol*. 1998;37:911-917.
19. Staley BA, Vail EA, Thiele EA. Tuberous sclerosis complex: diagnostic challenges, presenting symptoms, and commonly missed signs. *Pediatrics*. 2011;127:e117-e125.
20. Yates JRW, MacLean C, Higgins JNP, et al. The tuberous sclerosis 2000 study: presentation initial assessments and implications for diagnosis and management. *Arch Dis Child*. 2011;96:1020-1025.
21. Webb D, Clarke A, Fryer A, Osborne J. The cutaneous features of tuberous sclerosis: a population study. *Br J Dermatol*. 1996;135:1-5.
22. Alper J, Holmes L. The incidence and significance of birthmarks in a cohort of 4,641 newborns. *Pediatr Dermatol*. 1983;1:58-68.
23. Vanderhooft S, Francis J, Pagon R, Smith L, Sybert V. Prevalence of hypopigmented macules in a healthy population. *J Pediatr*. 1996;129:355-361.
24. Jozwiak S, Schwartz RA, Janniger CK, Bielicka-Cymerman J. Usefulness of diagnostic criteria of tuberous sclerosis complex in pediatric patients. *J Child Neurol*. 2000;15:652-659.
25. Bansal C, Stewart D, Li A, Cockerell C. Histologic variants of fibrous papule. *J Cutan Pathol*. 2005;32:424-428.
26. Darling TN, Skarulis MC, Steinberg SM, Marx SJ, Spiegel AM, Turner M. Multiple facial angiofibromas and collagenomas in patients with multiple endocrine neoplasia type 1. *Arch Dermatol*. 1997;133:853-857.
27. Toro J, Glenn G, Duray P, et al. BHD mutations, clinical and molecular genetic investigations of Birt-Hogg-Dubé syndrome: a new

series of 50 families and a review of published reports. *J Med Genet*. 2008;45:321-333.
28. Aldrich CS, Hong CH, Groves L, Olsen C, Moss J, Darling TN. Acral lesions in tuberous sclerosis complex: insights into pathogenesis. *J Am Acad Dermatol*. 2010;63:244-251.
29. Zeller J, Friedmann D, Clerici T, Revuz J. The significance of a single periungual fibroma: report of seven cases. *Arch Dermatol*. 1995;131: 1465-1466.
30. Toro J, Glenn G, Duray P, et al. Birt-Hogg-Dubé syndrome: a novel marker of kidney neoplasia. *Arch Dermatol*. 1999;10:1195-1202.
31. Darling T, Moss J, Mausner M. Dermatologic manifestations of tuberous sclerosis complex (TSC). In: Kwiatkowsi D, Whittemore V, Thiele E, eds. *Tuberous Sclerosis Complex: Genes, Clinical Features, and Therapeutics*. Weinheim: Wiley-Blackwell; 2010.
32. Mlynarczyk G. Enamel pitting: a common symptom of tuberous sclerosis. *Oral Surg Oral Med Oral Pathol*. 1991;71:63-67.
33. Lygidakis N, Lindenbaum R. Oral fibromatosis in tuberous sclerosis. *Oral Surg Oral Med Oral Pathol*. 1989;68:725-728.
34. Sparling J, Hong C, Brahim J, Moss J, Darling T. Oral findings in 58 adults with tuberous sclerosis complex. *J Am Acad Dermatol*. 2007; 56:786-790.
35. Bataineh A, Al-Dwairi N. A survey of localized lesions of oral tissues: a clinicopathological study. *J Contemp Dent Pract*. 2005;6:30-39.
36. Ono Y, Takahashi H, Inagi K, Nakayama M, Okamoto M. Clinical study of benign lesions in the oral cavity. *Acta Otolaryngol Suppl*. 2002;547:79-84.
37. Aronow M, Nakagawa J, Gupta A, Traboulsi E, Singh A. Tuberous sclerosis complex: genotype/phenotype correlation of retinal findings. *Ophthalmology*. 2012;199:1917-1923.
38. Rowley S, O'Callaghan F, Osborne J. Ophthalmic manifestations of tuberous sclerosis: a population based study. *Br J Ophthalmol*. 2001; 85:420-423.
39. Li L, Li N, Zhao J, et al. Findings of perinatal ocular examination performed on 3573, healthy full-term newborns. *Br J Ophthalmol*. 2013;97:588-591.
40. Franz D. Non-neurologic manifestations of tuberous sclerosis complex. *J Child Neurol*. 2004;19:690-698.
41. Northrup H, Wheless J, Bertin T, Lewis R. Variability in expression in tuberous sclerosis. *J Med Genet*. 1993;30:101-103.
42. Crino P, Mehta R, Vinters H. Pathogenesis of TSC in the brain. In: Kwiatkowsi D, Whittemore V, Thiele E, eds. *Tuberous Sclerosis Complex: Genes, Clinical Features, and Therapeutics*. Weinheim: Wiley-Blackwell; 2010:285-309.
43. Black M, Kadlez M, Smallhorn J, Freedom R. Cardiac rhabdomyomas and obstructive left heart disease: histologically but not functionally benign. *Ann Thorac Surg*. 1998;65:1388-1390.
44. Freedom RM, Lee KJ, MacDonald C, Taylor G. Selected aspects of cardiac tumors in infancy and childhood. *Pediatr Cardiol*. 2000;21: 299-316.
45. Tworetzky W, McElhinney DB, Margossian R, et al. Association between cardiac tumors and tuberous sclerosis in the fetus and neonate. *Am J Cardiol*. 2003;92:487-489.
46. Beghetti M, Gow R, Haney I, Mawson J, Williams W, Freedom R. Pediatric primary benign cardiac tumors: a 15-year review. *Am Heart J*. 1997;134:1107-1114.
47. Harding C, Pagon R. Incidence of tuberous sclerosis in patients with cardiac rhabdomyoma. *Am J Med Genet*. 1990;37:443-446.
48. Holley D, Martin G, Brenner J, et al. Diagnosis and management of fetal cardiac tumors: a multicenter experience and review of published reports. *J Am Coll Cardiol*. 1995;26:516-520.
49. Johnson SR, Cordier JF, Lazor R, et al. European Respiratory Society guidelines for the diagnosis and management of lymphangioleiomyomatosis. *Eur Respir J*. 2010;35:14-26.
50. McCormack F, Henske E. Lymphangioleiomyomatosis and pulmonary disease in TSC. In: Kwiatkowsi D, Whittemore V, Thiele E, eds. *Tuberous Sclerosis Complex: Genes, Clinical Features, and Therapeutics*. Weinheim: Wiley-Blackwell; 2010.
51. Cudzilo C, Szczesniak R, Brody A, et al. Lymphangioleiomyomatosis screening in women with tuberous sclerosis. *Chest*. 2013;144: 578-585.
52. Adriaensen ME, Schaefer-Prokop CM, Duyndam DA, Zonnenberg BA, Prokop M. Radiological evidence of lymphangioleiomyomatosis in female and male patients with tuberous sclerosis complex. *Clin Radiol*. 2011;66:625-628.
53. Muzykewicz D, Black M, Muse V, et al. Multifocal micronodular pneumocyte hyperplasia: computed tomographic appearance and follow-up in tuberous sclerosis complex. *J Comput Assist Tomogr*. 2012;36:518-522.
54. Henske E, McCormack F. Lymphangioleiomyomatosis—a wolf in sheep's clothing. *J Clin Invest*. 2012;122:3807-3816.
55. Kobashi Y, Sugiu T, Mouri K, Irei T, Nakata M, Oka M. Clinicopathological analysis of multifocal micronodular pneumocyte hyperplasia associated with tuberous sclerosis in Japan. *Respirology*. 2008; 13:1076-1081.
56. Cancellieri A, Poletti V, Corrin B. Respiratory failure due to micronodular type II pneumocyte hyperplasia. *Histopathology*. 2002;41: 263-265.
57. Franz D, Brody A, Meyer C, et al. Mutational and radiographic analysis of pulmonary disease consistent with lymphangioleiomyomatosis and micronodular pneumocyte hyperplasia in women with tuberous sclerosis. *Am J Respir Crit Care Med*. 2001;164: 661-668.
58. Muzykewicz DA, Sharma A, Muse V, Numis AL, Rajagopal J, Thiele EA. TSC1 and TSC2 mutations in patients with lymphangioleiomyomatosis and tuberous sclerosis complex. *J Med Genet*. 2009; 46:465-468.
59. Martignoni G, Pea M, Reghellin D, Zamboni G, Bonetti F. PEComas: the past, the present and the future. *Virchows Arch*. 2008;452: 119-132.
60. Fricke BL, Donnelly LF, Casper KA, Bissler JJ. Frequency and imaging appearance of hepatic angiomyolipomas in pediatric and adult patients with tuberous sclerosis. *AJR Am J Roentgenol*. 2004;182: 1027-1030.
61. Shepherd C, Gomez M, Lie J, Crowson C. Causes of death in patients with tuberous sclerosis. *Mayo Clin Proc*. 1991;66:792-796.
62. Bissler J, Henske E. Renal manifestations of tuberous sclerosis complex. In: Kwiatkowsi D, Whittemore V, Thiele E, eds. *Tuberous Sclerosis Complex: Genes, Clinical Features, and Therapeutics*. Weinheim: Wiley-Blackwell; 2010.
63. Kozlowska J, Okon K. Renal tumors in postmortem material. *Pol J Pathol*. 2008;59:21-25.
64. Bissler J, Kingswood J. Renal angiomyolipomata. *Kidney Int*. 2004; 66:924-934.
65. Pei Y. Practical genetics for autosomal dominant polycystic kidney disease. *Nephron Clin Pract*. 2010;118:c19-c30.
66. Brook-Carter P, Peral B, Ward C, et al. Deletion of the TSC2 and PKD1 genes associated with severe infantile polycystic kidney disease—a contiguous gene syndrome. *Nat Genet*. 1994;8: 328-332.
67. O'Callaghan F, Osborne J. Endocrine, gastrointestinal, hepatic, and lymphatic manifestations of tuberous sclerosis complex. In: Kwiatkowski D, Whittemore V, Thiele E, eds. *Tuberous Sclerosis Complex: Genes, Clinical Features, and Therapeutics*. Weinheim: Wiley-Blackwell; 2010:369-385.
68. Compton W, Lester P, Kyaw M, Madsen J. The abdominal angiographic spectrum of tuberous sclerosis. *AJR Am J Roentgenol*. 1976; 126:807-813.
69. Bruneton J, Drouillard J, Rabin A, Boedec R, Broussin J, Delorme G. Angiomyolipomas (hamartomas) of the kidney. Radiology study apropos of 2 cases. Review of the literature. *J Can Assoc Radiol*. 1978; 29:252-261.
70. Noldus J, Ancker U, Schafer H, Conrad S, Huland H. Multilocular, giant angiomyolipoma of the kidney, adrenal gland, and para-aortic lymph nodes. Case report of a 9-year-old boy with tuberous sclerosis. *Der Urologe Ausg A*. 1994;33:353-356.
71. Perou M, Gray P. Mesenchymal hamartomas of the kidney. *J Urol*. 1960;83:240-261.
72. Verma B, Tailor M. Familial tuberous sclerosis: a review with report of three cases. *Indian Pediatr*. 1965;2:401-410.
73. Dworakowska D, Grossman AB. Are neuroendocrine tumours a feature of tuberous sclerosis? A systematic review. *Endocr Relat Cancer*. 2009;16:45-58.
74. Nakhleh RE. Angiomyolipoma of the liver. *Pathol Case Rev*. 2009;14: 47-49.

Appendix. Members of the 2012 International TSC Consensus Group

Conference co-chairs:	Hope Northrup MD (Houston, Texas)
	Darcy A. Krueger MD, PhD (Cincinnati, Ohio)
TS Alliance representatives:	Steven Roberds PhD (Silver Spring, Maryland)
	Katie Smith (Silver Spring, Maryland)
Genetics chair:	Julian Sampson DM, FRCP, FMedSci (Cardiff, Wales, UK)
Genetics committee:	Bruce Korf MD, PhD (Birmingham, Alabama)
	David J. Kwiatkowski MD PhD (Boston, Massachusetts)
	David Mowat MD (Sydney, New South Wales, Australia)
	Mark Nellist PhD (Rotterdam, The Netherlands)
	Hope Northrup MD (Houston, Texas)
	Sue Povey MD (London, England, UK)
TSC-associated neuropsychiatric disorders chair:	Petrus de Vries MBChB, MRCPsych, PhD (Cape Town, South Africa)
TSC-associated neuropsychiatric disorders committee:	Anna Byars PhD (Cincinnati, Ohio)
	David Dunn MD (Indianapolis, Indiana)
	Kevin Ess MD, PhD (Nashville, Tennessee)
	Dena Hook (Silver Spring, Maryland)
	Anna Jansen MD, PhD (Brussels, Belgium)
	Bryan King MD (Seattle, Washington)
	Mustafa Sahin MD, PhD (Boston, Massachusetts)
	Vicky Whittemore PhD (Bethesda, Maryland)
Epilepsy chair:	Elizabeth Thiele MD, PhD (Boston, Massachusetts)
Epilepsy committee:	E. Martina Bebin MD, MPA (Birmingham, Alabama)
	Harry T. Chugani MD (Detroit, Michigan)
	Peter Crino MD, PhD (Philadelphia, Pennsylvania)
	Paolo Curatolo MD (Rome, Italy)
	Greg Holmes MD (Lebanon, New Hampshire)
	Rima Nabbout MD, PhD (Paris, France)
	Finbar O'Callaghan MA, MB, MSc, PhD (Bristol, England, UK)
	James Wheless MD (Memphis, Tennessee)
	Joyce Wu MD (Los Angeles, California)
Dermatology and dentistry chair:	Thomas N. Darling MD, PhD (Bethesda, Maryland)
Dermatology and dentistry committee:	Edward W. Cowen MD, MHSc (Bethesda, Maryland)
	Elizabeth Gosnell DMD (Columbus, Ohio)
	Adelaide Hebert MD (Houston, Texas)
	Greg Mlynarczyk DDS (Santa Rosa, California)
	Keyomaurs Soltani, MD (Chicago, Illinois)
	Joyce Teng MD, PhD (Palo Alto, California)
	Mari Wataya-Kaneda MD, PhD (Osaka, Japan)
	Patricia M. Witman MD (Columbus, Ohio)
Nephrology co-chair:	Chris Kingswood MSc, FRCP (Brighton, England, UK)
Nephrology co-chair:	John Bissler MD (Cincinnati, Ohio)
Nephrology committee:	Klemens Budde MD (Berlin, Germany)
	John Hulbert MD (Edina, Minnesota)
	Lisa Guay-Woodford MD (Washington DC)
	Julian Sampson DM, FRCP, FMedSci (Cardiff, Wales, UK)
	Matthias Sauter MD (Munich, Germany)
	Bernard Zonneberg MD, PhD (Utrecht, The Netherlands)
Brain structure, tubers and tumors chair:	Sergiusz Jóźwiak MD, PhD (Warsaw, Poland)
Brain structure, tubers and tumors committee:	Ute Bartels MD, MSc (Toronto, Ontario, Canada)
	Moncef Berhouma MD (Lyon, France)
	David Neal Franz MD (Cincinnati, Ohio)
	Mary Kay Koenig MD (Houston, Texas)
	Darcy A. Krueger MD, PhD (Cincinnati, Ohio)
	E. Steve Roach MD (Columbus, Ohio,)
	Jonathan Roth MD (Tel Aviv, Israel)
	Henry Wang MD, PhD (Rochester, New York)
	Howard Weiner MD (New York, New York)
Pulmonology chair:	Francis X. McCormack MD (Cincinnati, Ohio)

Pulmonology committee:	Khalid Almoosa MD (Houston, Texas)
	Alan Brody MD (Cincinnati, Ohio)
	Charles Burger MD (Jacksonville, Florida)
	Vincent Cottin MD (Lyon, France)
	Geraldine Finlay MD (Boston, Massachusetts)
	Jennifer Glass MS (Cincinnati, Ohio)
	Elizabeth Petri Henske MD (Boston, Massachusetts)
	Simon Johnson MD (Nottingham, England, UK)
	Robert Kotloff MD (Philadelphia, Pennsylvania)
	David Lynch MD (Denver, Colorado)
	Joel Moss MD, PhD (Bethesda, Maryland)
	Karen Smith MLS (Bethesda, Maryland)
	Jay Rhu MD (Rochester, Minnesota)
	Angelo Taveira Da Silva MD, PhD (Bethesda, Maryland)
	Lisa R. Young MD (Nashville, Tennessee)
Cardiology chair:	Timothy Knilans MD (Cincinnati, Ohio)
Cardiology committee:	Robert Hinton MD (Cincinnati, Ohio)
	Ashwin Prakash MD (Boston, Massachusetts)
	Robb Romp MD (Birmingham, Alabama)
Ophthalmology chair:	Arun D. Singh MD (Cleveland, Ohio
Gastroenterology chair:	Ashish DebRoy MD (Houston, Texas, USA)
Endocrinology chair:	Pei-Lung Chen MD, PhD (Taipei, Taiwan)
Care Integration chair:	Steven Sparagana MD (Dallas, Texas)
Care integration committee:	Michael D. Frost MD (St. Paul, Minnesota)