


RESEARCH ARTICLE

Neurocutaneous syndromes in art and antiquities

Martino Ruggieri¹  | Amalia Egle Gentile² | Vincenza Ferrara³ | Massimo Papi⁴ |
Andrea D. Praticò¹ | Albert Mudry⁵ | Domenica Taruscio² | Giuseppe Micali⁶ |
Agata Polizzi⁷

¹Unit of Rare Diseases of the Nervous System in Childhood, Department of Clinical and Experimental Medicine, Section of Pediatrics and Child Neuropsychiatry, University of Catania, Catania, Italy

²National Centre for Rare Diseases, Istituto Superiore di Sanità, Rome, Italy

³Laboratories of Art and Medical Humanities, Faculty of Pharmacy and Medicine, Sapienza University of Rome, Rome, Italy

⁴National Institutes for Health, Migration and Poverty (NIHMP) and DermArt, Rome, Italy

⁵Department of Otolaryngology, Head and Neck Surgery, Stanford University School of Medicine, Stanford, California

⁶Unit of Clinical Dermatology, Department of General Surgery and Medical and Surgical Specialties, Section of Dermatology and Venereology, University of Catania, Catania, Italy

⁷Department of Educational Sciences, Chair of Pediatrics, University of Catania, Catania, Italy

Correspondence

Martino Ruggieri, Unit of Rare Diseases of the Nervous System in Childhood, Department of Clinical and Experimental Medicine, University of Catania, AOU "Policlinico," PO "G. Rodolico-San Marco," Via S. Sofia, 78, 95125 Catania, Italy.

Email: m.ruggieri@unict.it

Abstract

Neurocutaneous syndromes are a group of genetic disorders affecting the skin, the central and peripheral nervous system, and the eye with congenital abnormalities and/or tumors. Manifestations may also involve the heart, vessels, lungs, kidneys, endocrine glands and bones. When people with these disorders are portrayed in works of art, physicians have speculated on possible diagnoses. In particular, many figures have been labeled as possibly having a neurocutaneous disorder, sometimes distorting the popular conception of these diseases. We review numerous documents, drawings, prints, lithographs, xylographs, and portraits which span the ages from antiquity to the era of the pioneers behind the eponyms, depicting a large spectrum of neurocutaneous disorders.

KEYWORDS

artwork, disorders, neurocutaneous, painting, phacomatosis, print

1 | INTRODUCTION

1.1 | Definition of the neurocutaneous syndromes

In their current definition, neurocutaneous syndromes/disorders (or phacomatoses) are a heterogeneous group of genetic diseases affecting the skin, the eye, and the central and peripheral nervous systems.

Manifestations may involve many other organs and systems including heart, vessels, lungs, kidneys, endocrine glands, and bones (Gomez, 1987;

Islam & Roach, 2015; Ruggieri, Pascual-Castroviejo, & di Rocco, 2008). Nowadays, the most commonly used terms remain neurocutaneous syndromes and phacomatoses, which are used interchangeably.

1.2 | Origin of the name(s)

Three of these conditions, that is, von Recklinghausen neurofibromatosis (Von Recklinghausen, 1882), Bourneville tuberous sclerosis

This is an open access article under the terms of the Creative Commons Attribution License, which permits use, distribution and reproduction in any medium, provided the original work is properly cited.

© 2021 The Authors. *American Journal of Medical Genetics Part C: Seminars in Medical Genetics* published by Wiley Periodicals LLC.

(Bourneville, 1880; Bourneville & Brissaud, 1881), and encephalotrigeminal angiomatosis of Sturge (1871) and Weber (1929), were grouped under the umbrella name of “phakomatoses” by the Dutch ophthalmologist Jan van der Hoeve [1878–1952] (Van der Hoeve, 1932, 1933), who had coined the term from the Greek word *phakoma/phakomata*, meaning lentil, spot, lens-shaped, to define the retinal lesions recorded in tuberous sclerosis (Van der Hoeve, 1920, 1921) (Figure 1) and in neurofibromatosis (Van der Hoeve, 1923).

The synonym “neurocutaneous syndromes” came from the studies of the American neurologist Paul Ivan Yakovlev and the American psychiatrist Riley H. Guthrie. They established the key phenotypic and diagnostic roles of nervous system and skin in the complex medical conditions affecting some individuals seen at the Monson State Hospital for Epileptics in Massachusetts (Ashwal, 1990; Yakovlev & Guthrie, 1931). They named these disorders the neurocutaneous syndromes, or ectodermatoses, to explain the pathogenesis due to a common embryological origin from the neuroectodermal layer. The Belgian pathologist

Ludo van Bogaert came to similar conclusions (Van Bogaert, 1935), but called them neuroectodermal dysplasias (Ashwal, 1990).

The Dutch pathologist Sylvan E. Moolten (Moolten, 1942) named Bourneville tuberous sclerosis “tuberous sclerosis complex”, thus recognizing its multi-organ nature. He first introduced the terms hamartial, hamartoma, and hamartoblastoma, derived from the Greek verb *hamartánein*, which means “to miss the mark” or “to err” or “to fail.” Later, the American pediatric neurologist Manuel R. Gomez changed definitively the former concept of “phakoma/phakomata” into the more modern definition of “hamartia/hamartoma” (Gomez, 1987). Genodermatoses and neurocristopathies have been and still are sometimes used as alternative terms in the scientific literature (Ruggieri et al., 2020).

2 | NEUROCUTANEOUS SYNDROMES IN WORKS OF ART

As works of art, neurocutaneous syndromes have stimulated a voluminous literature (Ashrafian, 2017; Lidden, 2006; Om & Om, 2018; Ponti et al., 2016; Ruggieri, Praticò, Caltabiano, & Polizzi, 2018; Ruggieri, Praticò, & Polizzi, 2020), which reflect wide differences of opinion (Ruggieri, Praticò, Scuderi, et al., 2017; Ruggieri, Praticò, Serra, et al., 2017; Ruggieri, Praticò, Catanzaro, Palmucci, & Polizzi, 2018). Only in the 19th and 20th centuries have these syndromes become better understood (Ashwal, 1990; Beighton & Beighton, 1986, 1997; Gomez, 1987; Ruggieri, Micali, & Praticò, 2018), even though the popular representations of affected individuals, both in real life (Cohen Jr., 1986; Howell & Ford, 1983) and in fiction (Cox, 1985; Solomon, 1968), created misconceptions and often conflated the various syndromes (Ruggieri, Praticò, Caltabiano, & Polizzi, 2018; Ruggieri, Praticò, & Polizzi, 2020).

This article will focus on selected artistic renditions from the old ages until contemporary times. We will list the artworks described herein according to the most recent classification of neurocutaneous syndromes (Ahn, Jackler, & Lustig, 1996; Huson, 1994; Ruggieri, Praticò, Caltabiano, & Polizzi, 2018; Ruggieri, Polizzi, et al., 2020a).

3 | THE NEUROFIBROMATOSES

Three forms have been recognized under the umbrella term of *neurofibromatosis*, including neurofibromatosis Type 1 (NF1) (Von Recklinghausen, 1882), neurofibromatosis Type 2 (NF2) (Gardner & Turner, 1940; Wishart, 1822) and *schwannomatosis* (MacCollin, Woodfin, Kronn, & Short, 1996). These are autosomal dominant conditions caused by different genes, which share common clinical features, including hyperpigmented birthmarks of the skin, congenital anomalies (e.g., bone and/or vascular dysplasias), and a predisposition to develop benign and, less frequently, malignant tumors of the central and peripheral nervous system but also of other organs and systems (Ferner et al., 2019; Halliday, Parry, & Evans, 2019; Plotkin & Wick, 2018; Ruggieri et al., 2016).

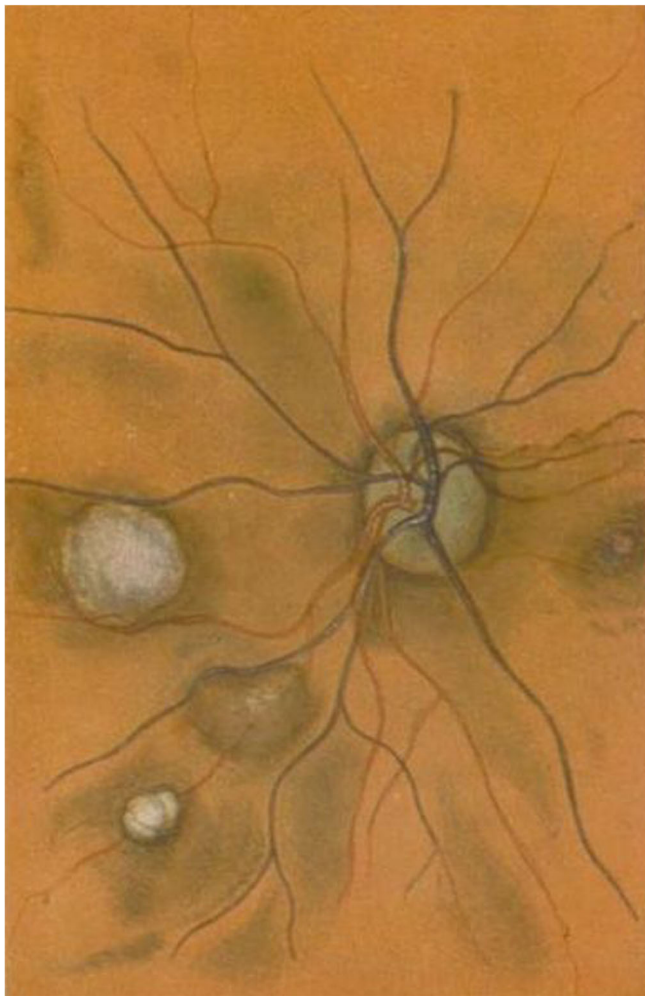

FIGURE 1 The original color print used by Jan van der Hoeve to depict the retinal “phakomas” seen as whitish/gray oval lesions in the central and left retina in the fundus of a patient with tuberous sclerosis. Copyright © The British Medical Council Library, London, UK

3.1 | Neurofibromatosis Type 1

3.1.1 | Multiple skin nodules in an enigmatic Hellenistic statuette [331–23 BC]

This statuette (Figure 2a) probably belongs to the Hellenistic period (323–31 BC) and originates from the Aegean town of Smyrna, in Anatolia. A healthy male with trunk and part of limbs is partially covered with multiple smooth, sessile nodules, resembling cutaneous neurofibromas. Some authors have suggested that it could have been a medical teaching aid while others hypothesized that it was more probably a decorative figure, maybe a satyr or a humanoid being, possibly a votive offer to the divinity (Gourevitch & Grmek, 1994; Linden, 1994; Ragge & Munier, 1994).

3.1.2 | Facial rounded nodules in the coins' effigies of the kings of Parthia [ca. 100 BC]

Parthia was located between northeastern Iran and Turkmenistan. Much of the knowledge on the aspects of the kings of Parthia arises from the coins (Daryae, 2017; Faghfoury, 2020). Centuries before, Alexander the Great had established the typical pattern of the empire's coin: a right-facing profile of a divinity on the obverse and a full-length deity on the reverse (Faghfoury, 2020). This pattern changed after the third century BC, when the rulers' own portraits started to appear in their left facing profile (Selwood, 1971). The first Parthian king to start issuing coins was Mithridates I [171–138 BC] (Selwood, 1971; Todman, 2008). The kings' representations in the coins are characteristic and realistic and it is possible to identify changes in the hairstyles and beards (Faghfoury, 2020;

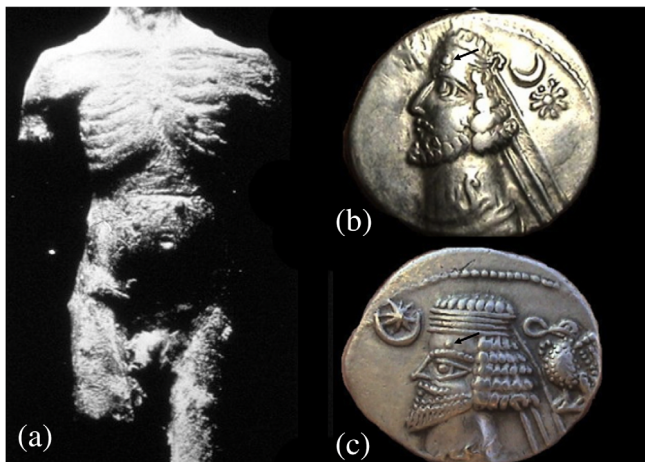


FIGURE 2 (a) Hellenistic statuette, representing a partial adult male body covered with multiple, smooth and sessile nodules, interpreted as neurofibromas. Copyright © 1994 Nature Publishing Group; (b,c) coins of the Parthian empire reproducing the left face of king Orodes II (b) [50 BC], and king Phraates IV (c) [20 BC] each represented with a large and round nodule, supposedly a neurofibroma, in their forehead (black arrows). Copyright © Archives of www.parthia.com (photographs by Douglas Mudd and Bart Lewis)

Selwood, 1971; Widengren, 1983). In the coins representing Mithridates II [124–91 BC; coins issued in 100 BC circa], Orodes II [57–37 BC], Phraates IV [37–2 BC], and in many of the successive kings up to Vardanes II [58 AD], a large round nodule is clearly visible in the forehead (Figure 2b,c) (Ashrafian, 2011; Selwood, 1971; Todman, 2008). The presence of these nodules in many generations suggests a possible hereditary trait, like neurofibromas in NF1 (Ashrafian, 2011; Selwood, 1971; Todman, 2008). Other hypotheses include common warts, trichoepitelioma (Hart, 1966), or basal cell carcinomas in the case of Mithridates II (Ashrafian, 2011).

3.1.3 | A large mass in von Meigenberg's “Buch der Natur” [1309–1374]

Konrad von Meigenberg [1309–1374] was a Bavarian scholar and philosopher who wrote more than 30 treatises on theological, astronomical, physical, historical, and political issues. His *Buch der Natur*, the first book of natural history in the German language, was extremely popular and was printed seven times, in several editions, in the 15th century alone (Baltrusaitis, 1960; Lattis, 2007; Pfeiffer, 2012).

In the 12th Tome of the Ausgburg edition [1475 AD], in addition to various types of imaginative figures including the mythological single large-footed sciapod, the headless monster with six arms, the cynocephalus and the Cyclops, one can observe a woman (Figure 3) who, according to Choulant (1963), has a large goiter. According to Zanca and Zanca (1977, 1980) she has NF1 and to Ruggieri and Polizzi (2003) she bears an isolated plexiform neurofibroma shaped like an elongated sack fitting with the diagnosis of mosaic NF1.

3.1.4 | Federico da Montefeltro's facial lesions and dysplasia by Piero della Francesca [1472]

The Duke Federico III da Montefeltro [1422–1480 AD] was one of the most famous Italian Condottieri (military chieftains) of the Renaissance and Lord of Urbino. He was said to have lost his right eye during a tournament, carrying for the rest of his life a vast and disfiguring scar, so that it was necessary to portray him only on his “good” side: that is, the left profile (Roeck & Tonnesmann, 2009; Stevenson, 2021; Tommasoli, 1978; <http://www.gallerianazionalemarche.it/palazzo-ducale/storia-della-famiglia-montefeltro/>).

Om and Om (2018) hypothesize, based on the portrait by Piero della Francesca (Figure 4) (<https://www.uffizi.it/opere/i-duchi-di-urbino-federico-da-montefeltro-e-battista-sforza>), that Montefeltro had several benign intradermal nevi, in the form of dome-shaped, skin-colored papules. These lesions, however, could also be attributed to small dermal neurofibromas, and the fact that he lost his right eye in a tournament has also been questioned, as he could have undergone surgical removal of an optic glioma and associated plexiform neurofibroma and dysplasia of the orbits. Notably, disruption of the orbit, either by trauma or surgery, may have invaded the root of the nose, whose shape is quite unusual (Ruggieri, Praticò, Caltabiano, & Polizzi, 2018).



FIGURE 3 Close view-up of a xylograph contained in the 12th Tome of Konrad von Megenberg's "Buch der Natur" [1475] representing a woman with large goiter, presumably a plexiform neurofibroma. Copyright © The Library of Congress, Washington, DC

3.1.5 | The infant of Chieri in Ambroise Paré's *Des monstres et prodiges* [1578 AD]

Ambroise Paré [1510–1590] was a famous French barber surgeon who cared for soldiers in battle. He was the official royal surgeon for several kings and is considered one of the fathers of surgery who developed surgical techniques and battlefield medicine, especially the treatment of wounds. He was also an anatomist and the inventor of several surgical instruments and authored many books on anatomy, surgery and medicine (Céard, 1971; Hambry, 1967).

Among the various figures in his book *Des monstres et prodiges* (On Monsters and Marvels) (Pallister, 1995) is an infant born near Turin, Italy (Figure 5a) (Zanca & Zanca, 1977, 1980). The face "...was well-proportioned in every way, but there were five horn-like growths on the head and a long, fleshy mass hanging down from the head along the back "like a woman's hat...another double fleshy mass like a shirt collar was visible around the neck". This fleshy mass hanging down along the back was diagnosed as a solitary plexiform neurofibroma (i.e., mosaic NF1) (Ruggieri & Polizzi, 2003; Ruggieri & Praticò, 2015).



FIGURE 4 Portrait of the Duke Federico da Montefeltro by Piero della Francesca: note the multiple warts on his left face interpreted either as fibrous nodules or neurofibromas. Copyright © Galleria degli Uffizi, Firenze, Italy

However, this severe anomaly is likely exaggerated and certainly inaccurate. Paré did not observe the case first-hand, but obtained this drawing from a 1,578 pamphlet in Chambery (Pallister, 1995). Notably, Paré's sketch of this infant, with the less than believable claw-like digits and horns, represents a fairly standard view of the relationship between human disorders and the conception of "monsters" during the 16th century (Brosius, 2010; Céard, 1971; Ruggieri & Polizzi, 2003; Ruggieri, Praticò, Caltabiano, & Polizzi, 2018).

3.1.6 | A large fleshy mass in Aldrovandi "homuncio" [Monstrorum Historia—1592]

Ulisse Aldrovandi [1522–1605], native of Bologna, was an Italian physician, philosopher, and naturalist (Caprotti, 1980; Simili, 2001; Tega, 2002). He was the driving force behind the construction of Bologna's botanical garden, one of the first in Europe, and of a most spectacular cabinet of curiosities, illuminating natural history and comprising some 18,000 "different examples of natural things," and 7,000 "specimens of dried plants," representing the "diversità di cose naturali" ("diversity of natural things") (Simili, 2001; Tega, 2002; Wittkower, 1942).

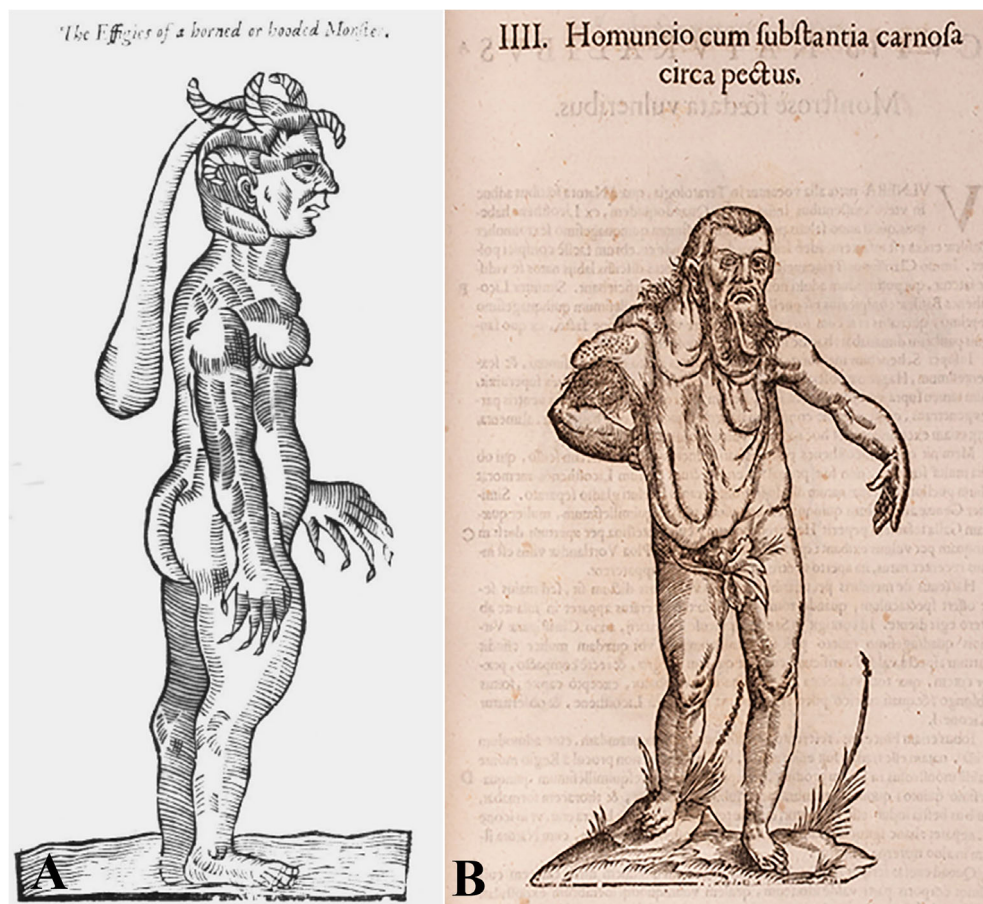

FIGURE 5 (a) The imaginative “infant of Chieri” by Ambroise Paré: the fleshy mass hanging down along the back was interpreted as a plexiform neurofibroma. Copyright © Wellcome Library London, UK; (b) Aldrovandi’s “homuncio,” with enormous, flabby masses of flesh, hanging from his right side, likely representing a plexiform neurofibroma in mosaic neurofibromatosis type 1 (NF1). Copyright © Biblioteca Universitaria di Bologna, Italy

In 1592, Aldrovandi recorded the extraordinary case of a man of low stature (homuncio), of Indian origin who presented enormous, flabby masses of flesh hanging from the left side of his head and trunk (Figure 5b) published posthumously (Aldrovandi, 1642). Some Italian Authors (Zanca, 1975; Zanca and Zanca, 1977, 1980; Zanca & Tagliavini, 1980) inferred that this misshapen man may represent a case of NF1, based on: (a) the appearance of the masses, which look like plexiform neurofibromas covered with hair, similar to the hairy nevi seen over plexiform neurofibromas in NF1; and (b) the short stature of the subject, a minor NF1 feature (Morse, 1999; Mulvihill, 1988). Madigan and Masello (1989) added a third NF1 feature, that is, macrodactyly of the left second toe and leg asymmetry secondary to scoliosis. Ruggieri and Polizzi (2003) proposed that the diagnosis of the homuncio would fit better with mosaic NF1 (Ruggieri & Praticò, 2015) rather than classical NF1 as the large fleshy mass (i.e., the plexiform neurofibroma) is solitary and there are no other NF1 stigmata either in the print or in the accompanying Latin text (Aldrovandi, 1642).

3.1.7 | The raised skin macules in Buffon's *Histoire Naturelle* girl [1749]

Comte Georges Louis Leclerc de Buffon [1707–1788] was a French naturalist, mathematician, cosmologist and encyclopedic author. Ten years after becoming the curator of the King's garden in Paris, he began publishing his 38 volumes of *Histoire Naturelle* (Natural History),

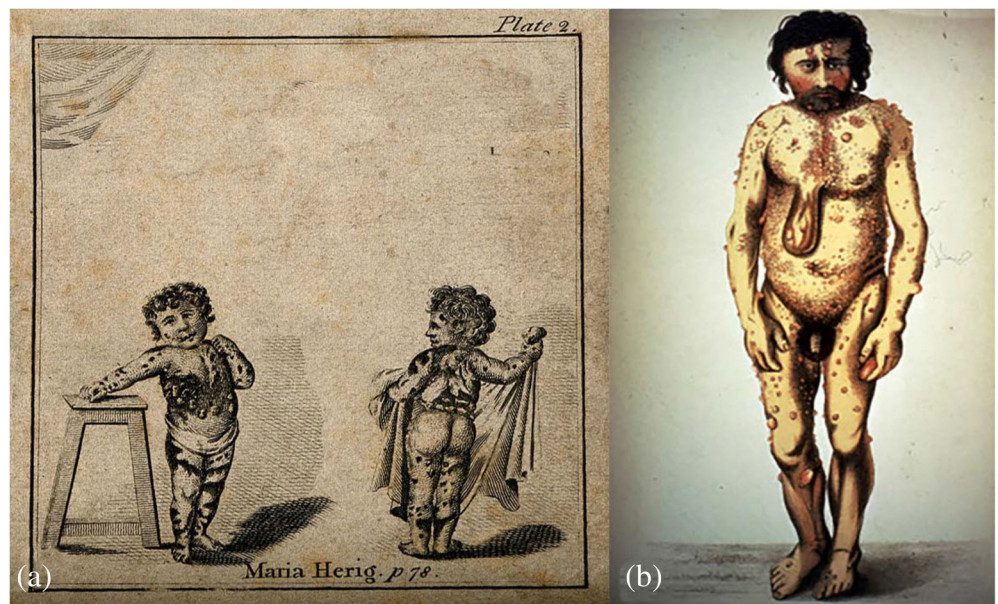a compendium of the natural history of animals and minerals, published over 40 years and continued posthumously (Hecht, 1989; Leclerc de Buffon, 2014; Madigan & Masello, 1989; Roule, 1924).

In one of the tables in the 1707–1788 edition there is a color drawing by B. de Bakker of a girl [Maria Herig] (Figure 6a, bottom) who shows different types of cutaneous anomalies: (a) multiple dark leaf-shaped areas of hyperpigmentation in the limbs and trunk, possibly café-au-lait spots; (b) a large, “life vest-” shaped lesion encircling the trunk, a possibly a diffuse cutaneous plexiform neurofibroma (Huson, 1994; Ruggieri & Polizzi, 2003). An alternative diagnosis is an epidermal sebaceous nevus with satellite lesions (Ruggieri, Praticò, Caltabiano, & Polizzi, 2018).

3.1.8 | The “Wart Man” of Tilesius von Tilenau [1793]

Tilesius von Tilenau (1769–1857) was a German physician, naturalist and explorer. In 1793, he reported on a case called the “Wart Man” (Tilesius von Tilenau, 1793). This patient, Johan Gottfried Reinhardt, was reported under the title “Case History of Extraordinary Unightly Skin” and described as having “countless growths [fibrous tumours] on the skin, café-au-lait spots, macrocephaly, and scoliosis.” In a color reproduction (Figure 6b) of the original illustration accompanying the case presentation one can note a fleshy mass hanging forward toward the abdomen. The latter might be a pedunculated

FIGURE 6 (a) Lithograph depicting Maria Herig with multiple dark leaf-shaped areas of hyper pigmentation of the skin (likely café-au-lait spots) in the limbs and in the trunk and a large, raised “pigskin” encircling lesion over her trunk (likely a cutaneous plexiform neurofibroma or an epidermal nevus). Copyright © Wellcome Library London, UK; (b) von Tilenau's “Wart Man”. © Authors' personal collection



diffuse cutaneous plexiform neurofibroma (Ruggieri, Praticò, Caltabiano, & Polizzi, 2018).

4 | TUBEROUS SCLEROSIS COMPLEX

Tuberous sclerosis (Bourneville, 1880–1881) is a complex multi-system tumor-predisposing syndrome characterized by the appearance of cutaneous hypomelanotic birthmarks and fibrous and capillary benign tumors of the skin and skin appendages including forehead plaques, facial angiofibromas, shagreen plaques, fibromas and ungual fibromas; cardiac rhabdomyomas, renal and/or systemic angiomyolipomas, retinal hamartomas; and brain malformations including cortical tubers, hamartomas, subependymal nodules, or subependymal giant cell astrocytomas (Curatolo, Bombardieri, & Jozwiak, 2008; Northrup et al., 2013). Affected people may develop seizures, mental and behavioral disabilities, and organ damage secondary to tumor progression (Krueger et al., 2013; Northrup et al., 2013; Ruggieri, Polizzi, et al., 2020).

4.1 | The facial “végétations vasculaires” and “adenoma sebaceum”

An early possible illustration of one of the skin manifestations of tuberous sclerosis, facial angiofibromas, is given in 1835 by the French physician, pathologist, physiologist, parasitologist and dermatologist Pierre François Olive Rayer [1793–1867] (Théodoridès, 1995) in his atlas of skin disorders entitled *Traité Teorique e Pratique des Maladies de la Peau* (Theoretical and Practical Treatise on Skin Diseases) (Rayer, 1835) (<https://www.cppdigitallibrary.org/collections/browse>). On page 20, Figure 1 (Figure 7a) shows a young man's face dotted with clusters of small, erythematous papules [végétations vasculaires]

with a characteristic distribution and similar appearance to the typical facial angiofibromas: “...small... of vascular appearance, widespread growths distributed on the nose and around the mouth...” No mention was made of any medical condition associated with the skin disorder (Curatolo, 2003; Jay, 1999).

Drawings and portraits of women (Figure 7b) and men (Figure 7c) represented with facial angiofibromas [at that time known as “adenoma sebaceum” as it was believed that the sebaceous glands were the source of the problem] (Balzer & Ménétrier, 1885; Curatolo, 2003; Gomez, 1995; Hallopeau & Leredde, 1885; Jay, 1999; Pringle, 1890) were common at the turn of the 19th century.

4.2 | “Sclerotic islands and tumors” in the lithographs by Eduard Brissaud [1880]

The French physician, neurologist, neuropathologist and later Paris councilman and Deputy member of the French Parliament, Desiré Magloire Bourneville [1833–1910] provided the first (Bourneville, 1880–1881) and second (Bourneville & Brissaud, 1881) detailed clinical and neuropathological description of tuberous sclerosis in two children, Marie and George. The 15-year-old Marie, hospitalized in Paris at La Pitié Salpêtrière since the age of 3 years and who had died secondary to the complications of status epilepticus, had the typical skin lesions of tuberous sclerosis and a history of severe psychomotor delay, learning and language difficulties, behavioral stereotypes, spastic hemiplegia and recurrent episodes of status epilepticus since the age of 2 years and was eventually declared a “hopeless case.” At postmortem examination, her brain revealed various whitish, opaque, dense, hypertrophic sclerotic islands (i.e., cortical tubers) alongside small sclerous clusters of tumors in the external walls of the lateral ventricles (i.e., subependymal nodules) (Brigo et al., 2018; Gomez, 1995). To describe the peculiarity of this cerebral pathology

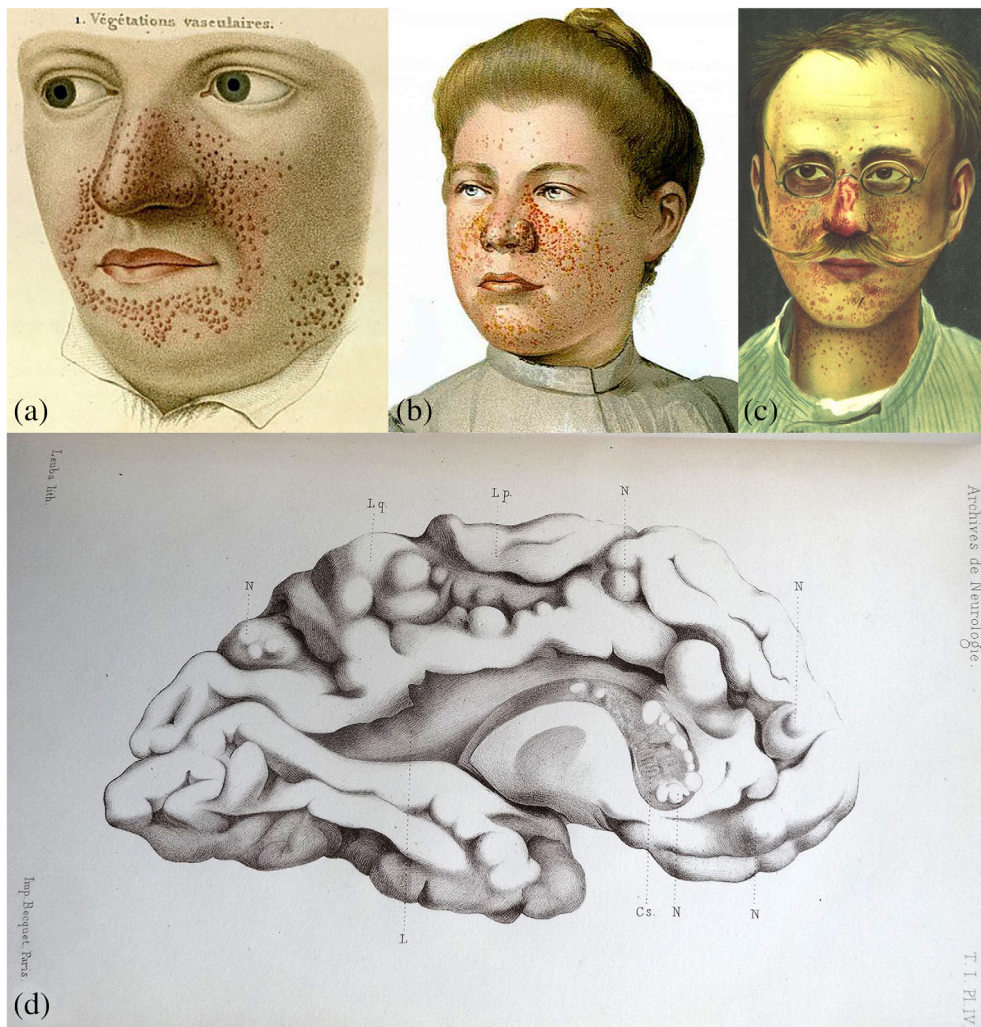


FIGURE 7 (a) A young man's face dotted with clusters of small, erythematous papules [végétations vasculaires] interpreted by Rayer as typical facial angiofibromas: Copyright © Wellcome Library, London, UK; (b,c) two 20th century prints depicting facial “adenoma sebaceum” (i.e., the old term used for the facial angiofibromas): Copyright © Wellcome Library, London, UK; (d) Drawings of the brain of the 15-year-old Marie: note the “sclerotic” cortical “tubers” and the “subependymal tumors” (nodules) of the lateral walls of the ventricles: Copyright © Wellcome Library, London, UK

Bourneville coined the term “*Sclérose tubéreuse des circonvolutions cérébrales*” (tuberous sclerosis of the cerebral circonvolutions) and asked his friend and colleague Eduard Brissaud [1852–1909] to depict Marie's brain findings (Figure 7d).

5 | HYPOMELANOSIS OF ITO AND THE LINES OF BLASCHKO

There is a heterogeneous group of disorders, so far attributed to chromosomal abnormalities, which are characterized by the occurrence of hypopigmented and hyperpigmented skin birthmarks in the form of whorls, streaks, V-shaped, or S-shaped alterations following the so-called Lines of Blaschko, which represent a nonrandom, nonvisible embryological system of lines followed by pigmentary cells during development (Blaschko, 1901; Bologna, Orlow, & Glick, 1994; Happle, 1993, 2014; Kromann, Ousager, Ali, Aydemir, & Bygum, 2018; Ruggieri, Polizzi, et al., 2020; Salas-Labadía et al., 2019). These disorders have been collectively named “pigmentary mosaicism”; however, some individuals with hypopigmented abnormalities

along the lines of Blaschko, may also have additional associated systemic involvement affecting principally the eyes, the musculoskeletal and nervous systems, thus configuring a complex neurocutaneous syndrome known as hypomelanosis of Ito (Ito, 1952), whose manifestations are cataracts, scoliosis, seizures, cognitive deficits, speech/language deficits, hypotonia, or abnormal EEGs (Ruggieri & Pavone, 2000; Ruggieri, Polizzi, et al., 2020).

5.1 | Alfred Blaschko and his system of lines: A precursor of “mosaicism”

Alfred Blaschko [1858–1922] was a private practitioner of dermatology in Berlin whose interests ranged from leprosy to occupational skin diseases (Bologna et al., 1994). In 1901, he presented his findings on the distribution patterns of linear skin disorders at the German Dermatological Society Meeting, in Breslau (Blaschko, 1901; <https://archive.org/stream/dienervenverteil00blas#page/n5/mode/2up>). He examined more than 140 patients with linear lesions such as epidermal nevi, sebaceous nevi, and nevus lipomatosus and carefully

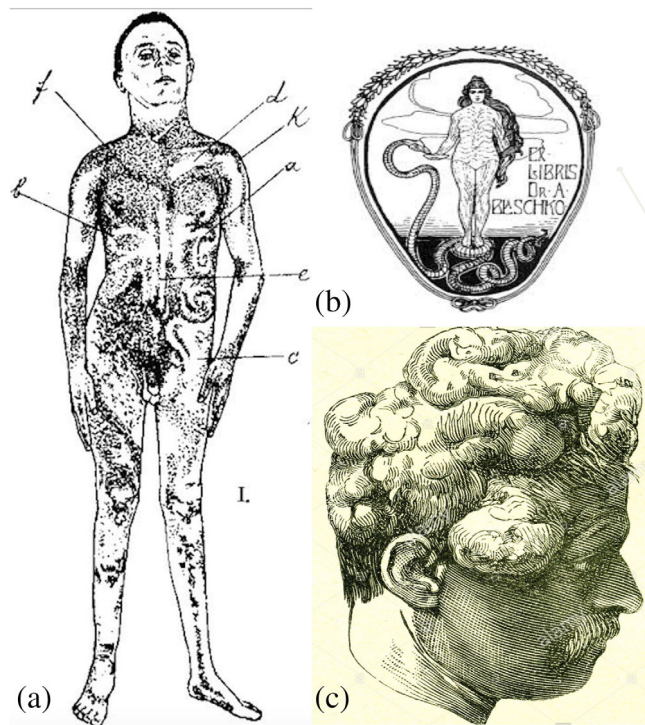


FIGURE 8 (a) One of the original drawings by Alfred Blaschko, depicting a child with the typical epidermal nevus lesions arranged according to specific lines of distribution of pigment, since called after his name and (b) Alfred Blaschko's bookplate, showing Hygieia, the Greek goddess of health, with the Blaschko lines superimposed. Copyright © The Cushing-Whitney Medical Library, Yale University; (c) a print from a book *Treatise of Medicine* [1889], depicting a man with multiple lipomas likely representing encephalocraniocutaneous lipomatosis

transposed the pattern in each patient onto dolls and statues used for illustrating his 1901 book (Figure 8a) (Blaschko, 1901). A composite diagram of these distribution patterns was then drawn that has subsequently been referred to as the Lines of Blaschko and applied in the liberty style cover of Blaschko's posthumous book (Figure 8b) (Happle, 1993).

6 | ENCEPHALOCRANIOCUTANEOUS LIPOMATOSIS [HABERLAND SYNDROME]

This mosaic neurocutaneous syndrome with lipomatous changes (Haberland & Perou, 1970) is characterized by the occurrence of multiple lipomas in the zygomatic/fronto-temporal area, nevus psiloparus, alopecic fatty tissue, nonscarring alopecia, focal dermal hypoplasia/aplasia, periocular skin tags, and hyperpigmentation along Blaschko's lines. Additional features include epi-bulbar choristoma, bone cysts, jaw tumors, extensive intracranial/intraspinal lipomas, cerebral asymmetry, arachnoid cysts, enlarged ventricles, leptomeningeal angiomas/capillary malformation, low-grade gliomas, seizures, and intellectual disability (Levy & Massey, 2015; Ruggieri, Polizzi, et al., 2020).

6.1 | Cranial protuberances in a 20th century medical treatise [1910]

A lithograph from a 20th century book *Treatise of Medicine* shows an illustration (Figure 8c) of the head and face of a man with large, rounded masses protruding from his head, supposedly consisting of multiple lipomas within the context of encephalocraniocutaneous lipomatosis.

7 | CONCLUSION

Neurocutaneous syndromes have been observed in numerous types of artworks through the millennia. We hope that readers will appreciate the art itself and the way of depicting and looking at these medical entities across the centuries and, ultimately, to view the humanity of the persons portrayed rather than their disorder, seen in the past as a "medical curiosity."

CONFLICT OF INTEREST

None.

DATA AVAILABILITY STATEMENT

Data are available upon request to the author.

ORCID

Martino Ruggieri  <https://orcid.org/0000-0002-2658-4249>

REFERENCES

- Ahn, M. S., Jackler, R. K., & Lustig, L. R. (1996). The early history of the neurofibromatoses. Evolution of the concept of neurofibromatosis type 2. *Archives of Otolaryngology - Head & Neck Surgery*, 122, 1240–1249.
- Aldrovandi, U. (1642). *Monstruorum Historia: Cum Paralipomenis Historiae omnium Animalium* (p. 1642). Bologna: Typis Nicolai Tibaldini.
- Ashrafian, H. (2011). Limb gigantism, neurofibromatosis and royal heredity in the Ancient World 2500 years ago: Achaemenids and Parthians. *Journal of Plastic, Reconstructive and Aesthetic Surgery*, 64, 557.
- Ashrafian, H. (2017). Leonardo da Vinci's Virgin of the Rocks: Perhaps the first depiction of congenital vascular malformation syndrome. *Italian Journal of Anatomy and Embryology*, 3, 155–156. <https://doi.org/10.13128/IJAE-22974>
- Ashwal, S. (1990). *The founders of child neurology*. San Francisco, CA: Norman Publishing.
- Baltrusaitis, J. (1960). *Reveil et prodiges. Le gothique fantastique* (Vol. 349, pp. 105–106). Paris: Armand Colin note 59.
- Balzer, F., & Ménétrier, P. (1885). Étude sur un cas d'adénomes sébacés de la face et du cuir. *Archives de Physiologie Normale et Pathologique. Third Series*, 6, 564–576.
- Beighton, P., & Beighton, G. (1986). *The man behind the Syndrome*. Berlin: Springer-Verlag.
- Beighton, P., & Beighton, G. (1997). *The persons behind the syndrome*. London: Springer.
- Blaschko, A. (1901). *Die Neven-Verteilung in der Haut in ihrer Beziehung zu den Erkrankungen der Haut. Beilage zu den Verhandlungen der Deutschen Dermatologischen Gesellschaft VII Congress, Breslau*.

- Bolognia, J. L., Orlow, S. J., & Glick, S. A. (1994). Lines of Blaschko. *Journal of the American Academy of Dermatology*, 31, 157–190. [https://doi.org/10.1016/s0190-9622\(94\)70143-1](https://doi.org/10.1016/s0190-9622(94)70143-1)
- Bourneville, D. (1880). Sclérose tubéreuse des circonvolutions cérébrales: Idiotie et épilepsie hémiplégique. *Archives de Neurologie (in French)*, 1, 81–91.
- Bourneville, D., & Brissaud, È. (1881). Encéphalite ou sclérose tubéreuse des circonvolutions cérébrales. *Archives des Neurologie (Paris)*, 1, 390–412.
- Brigo, F., Trinka, E., Nardone, R., Bragazi, N. L., Ruggieri, M., ... Walusinski, O. (2018). First descriptions of tuberous sclerosis by Désiré-Magloire Bourneville (1840-1909). *Neuropathology*, 38, 577–582. <https://doi.org/10.1111/neup.12515>
- Brosius, S. (2010). A history of von Recklinghausen's NF1. *Journal of the History of the Neurosciences*, 19, 333348.
- Caprotti, E. (1980). *Mostri, Draghi e Serpenti nelle Silografie di Ulisse Aldrovandi e dei suoi Contemporanei*. Milano: Mazzotta editore.
- Céard, J. (1971). *Ambroise Paré. Des Monstres et prodiges* (p. 101). Edition critique e commentée. Geneve: Librairie Droz.
- Choulant, L. (1963). *Grapische Incunabeln fr Naturgeschichte und Medizin. Leipzig, 1858* (p. 113). Hildesheim: Georg Olms.
- Cohen, M. M., Jr. (1986). The elephant man did not have neurofibromatosis. *Proceedings of Greenwood Genetic Center*, 6, 187–192.
- Cox, J. (1985). Quest for Quasimodo (V. Hugo). *British Medical Journal (Clinical Research Ed.)*, 291, 1801–1803.
- Curatolo, P. (2003). *Tuberous sclerosis complex. From basic science to clinical phenotypes*. New York, NY: Wiley.
- Curatolo, P., Bombardieri, R., & Jozwiak, S. (2008). Tuberous sclerosis. *The Lancet*, 372, 657–668. [https://doi.org/10.1016/S0140-6736\(08\)61279-9](https://doi.org/10.1016/S0140-6736(08)61279-9)
- Daryae, T. (2017). Kings of the seven climes. In *A history of ancient Iranian world (300 BCE – 651 Ce)*. Irvine, CA: UCI Jordan Centre for Persian Studies.
- Faghfoury, M. (2020). Ancient Iranian Numismatics. In *Memory of David Sellwood*. BRILL, Leiden: Jordan Centre for Persian Studies.
- Ferner, R. E., Bakker, A., Elgersma, Y., Evans, D. G. R., Giovannini, M., Legius, E., ... Sherman, L. S. (2019). From process to progress-2017 international Conference on Neurofibromatosis 1, Neurofibromatosis 2 and Schwannomatosis. *American Journal of Medical Genetics - Part A*, 179, 1098–1106. <https://doi.org/10.1002/ajmg.a.61112>
- Gardner, W. J., & Turner, O. (1940). Bilateral acoustic neurofibromas. Further clinical and pathologic data on hereditary deafness and von Reckling-Hausen's disease. *Archives of Neurology and Psychiatry*, 44, 76–99.
- Gomez, M. R. (1987). Neurocutaneous diseases. In *A practical approach*. Boston, MA: Butterworths.
- Gomez, M. R. (1995). History of the tuberous sclerosis. *Brain and Development*, 17, 55–57. [https://doi.org/10.1016/0387-7604\(94\)00130-8](https://doi.org/10.1016/0387-7604(94)00130-8)
- Gourevitch, D., & Grmek, M. D. (1994). Enigmatic statue. *Nature*, 372, 228.
- Haberland, C., & Perou, M. (1970). Encephalocraniocutaneous lipomatosis. A new example of ectomesodermal dysgenesis. *Archives of Neurology*, 22, 144–155.
- Halliday, D., Parry, A., & Evans, D. G. (2019). Neurofibromatosis type 2 and related disorders. *Current Opinion in Oncology*, 31, 562–567. <https://doi.org/10.1097/CCO.0000000000000579>
- Hallopeau, F., & Leredde, È. (1885). Sur un cas d'adenomes sébacés à forme scléreuse. *Annales de Dermatologie et de Syphiligraphie*, 6, 473–479.
- Hambry, W. B. (1967). *Ambroise Paré surgeon of the renaissance*. New York, NY: Warren H Green.
- Happle, R. (1993). An early illustration of Blaschko's lines. *British Journal of Dermatology*, 128, 464. <https://doi.org/10.1111/j.1365-2133.1993.tb00212.x>
- Happle, R. (2014). *Mosaicism in human skin. Understanding nevi, nevoid skin disorders, and cutaneous neoplasia* (pp. 13–37). Berlin: Springer-Verlag.
- Hart, G. D. (1966). Trichoepithelioma and the kings of ancient Parthia. *Canadian Medical Association Journal*, 94(11), 547–549.
- Hecht, F. (1989). Recognition of neurofibromatosis before von Recklinghausen. *Neurofibromatosis*, 2, 180–184.
- Howell, M., & Ford, P. (1983). *The true history of the elephant man. A new edition of the story of Joseph Carey Merrick whose tragic life and extraordinary fate are told in this book*. London: Penuin Books.
- Huson, S. M. (1994). Neurofibromatosis: historical perspectives, classification and diagnostic criteria. In: S. M. Huson & R. A. C. Hughes (Eds.), *The neurofibromatoses: Pathogenetic and clinical overview* (pp. 1–22). London: Chapman & Hall.
- Islam, M. P., & Roach, E. S. (2015). Neurocutaneous syndromes. In *Handbook of clinical neurology* (3rd ed.). New York, NY: Elsevier.
- Ito, M. (1952). Studies of melanin XI. Incontinentia pigmenti achromians: A singular case of nevus depigmentosus systematicus bilateralis. *The Tohoku Journal of Experimental Medicine*, 55, 57–59.
- Jay, V. (1999). Historical contributions to pediatric pathology: Tuberous sclerosis. *Pediatric and Developmental Pathology*, 2, 197–198.
- Kromann, A. B., Ousager, L. B., Ali, I. K. M., Aydemir, N., & Bygum, A. (2018). Pigmentary mosaicism: A review of original literature and recommendations for future handling. *Orphanet Journal of Rare Diseases*, 13, 39. <https://doi.org/10.1186/s13023-018-0778-6>
- Krueger, D. A., Northrup, H., & International Tuberous Sclerosis Complex Consensus Group. (2013). Tuberous sclerosis complex surveillance and management: Recommendations of the 2012 International Tuberous Sclerosis Complex Consensus Conference. *Pediatric Neurology*, 49, 255–265. <https://doi.org/10.1016/j.pediatrneurol.2013.08.002>
- Lattis, J. M. (2007). Meigenberg, Konrad [Conrad] von. In T. Hockey, V. Trimble, Th. R. Williams, K. Bracher, R. Jarrell, J. D. Marché, & F. J. Ragep. (Eds.), *The biographical encyclopedia of astronomers*. New York, NY: Springer. https://doi.org/10.1007/978-0-387-30400-7_934
- Leclerc de Buffon, G. L. (2014). *Histoire naturelle de Buffon*. Paris: Place Vicotire.
- Levy, M. L., & Massey, C. (2015). Encephalocraniocutaneous lipomatosis. *Handbook of Clinical Neurology*, 132, 265–269. <https://doi.org/10.1016/B978-0-444-62702-5.00019-6>
- Lidden, K. (2006). Sin disease in antiquity. *Journal of the Royal College of Physicians of London*, 6, 81–86.
- Linden, D. E. (1994). Statue enigma. *Nature*, 369, 714.
- MacCollin, M., Woodfin, W., Kronn, D., & Short, M. P. (1996). Schwannomatosis: A clinical and pathologic study. *Neurology*, 46, 1072–1079. <https://doi.org/10.1212/wnl.46.4.1072>
- Madigan, P., & Masello, M. J. (1989). Report on a neurofibromatosis-like case: Monstruorum historia, 1642. *Neurofibromatosis*, 2, 53–56.
- Moolten, S. E. (1942). Hamartial nature of tuberous sclerosis complex and its bearings on the tumor problem: Report of a case with tumor anomaly of the kidney and adenoma sebaceum. *Archives of Internal Medicine*, 69, 589–623. <https://doi.org/10.1001/archinte.1942.0020160040005>
- Morse, P. (1999). Neurofibromatosis type 1. *Archives of Neurology*, 56, 364–365.
- Mulvihill, J. J. (1988). Neurofibromatosis: History, nomenclature and natural history. *Neurofibromatosis*, 1, 124–131.
- Northrup, H., Krueger, D. A., & International Tuberous Sclerosis Complex Consensus Group. (2013). Tuberous sclerosis complex diagnostic criteria update: Recommendations of the 2012 International Tuberous Sclerosis Complex Consensus Conference. *Pediatric Neurology*, 49, 243–254. <https://doi.org/10.1016/j.pediatrneurol.2013.08.001>
- Om, A., & Om, A. (2018). Integrating the integumentary system with the arts: A review of dermatologic findings in artwork. *The Journal of Clinical and Aesthetic Dermatology*, 11, 21–27.
- Pallister, J. L. (1995). *On monsters and marvels* (New ed., pp. 8–22). Chicago, IL: University of Chicago Press.
- Pfeiffer, F. (2012). *Das Buch der Natur von Konrad von Megenberg*. Berlin: Let Me Print.

- Plotkin, S. R., & Wick, A. (2018). Neurofibromatosis and Schwannomatosis. *Seminars in Neurology*, 38, 73–85. <https://doi.org/10.1055/s-0038-1627471>
- Ponti, G., Ruini, C., Pastorino, L., Loschi, P., Pecchi, A., Malagoli, M., ... Ruini, C. (2016). Wall paintings facies and their possible genetic correlates in the ancient Pompeii: A bio-anthropologic message from the past? *Gene*, 589, 151–156. <https://doi.org/10.1016/j.gene.2016.04.038>
- Pringle, J. J. (1890). A case of congenital adenoma sebaceum. *British Journal of Dermatology*, 2, 1–14.
- Ragge, N. K., & Munier, F. L. (1994). Ancient neurofibromatosis. *Nature*, 368, 815.
- Rayer, P. F. (1835). *Traité des maladies de la peau/atlas (in French)* (p. 20). Paris: J.B. Baillière.
- Roeck, B., & Tonnesmann, A. (2009). *Fedrico da Montefeltro. Arte, Stato e Mesteiere delle Armi*. Milano: Einaudi.
- Roule, L. (1924). Buffon et al description de la nature. In L. Roule (Ed.), *L'histoire de la nature vivante d'après l'ouvsres des Grands Naturalistes Francais* (Vol. 1). Paris: Flammarion.
- Ruggieri, M., Micali, G., & Praticò, A. D. (2018). Rare neurocutaneous disorders: State of the art and update. *Journal of Pediatric Neurology*, 16, 253–378.
- Ruggieri, M., Pascual-Castroviejo, I., & di Rocco, C. (2008). *Neurocutaneous disorders: Phakomatoses and Hamartoneoplastic syndromes*. New York, NY: Springer-Verlag.
- Ruggieri, M., & Pavone, L. (2000). Hypomelanosis of Ito: Clinical syndrome or just phenotype? *Journal of Child Neurology*, 15, 635–644. <https://doi.org/10.1177/088307380001501001>
- Ruggieri, M., & Polizzi, A. (2003). From Aldrovandi's Homuncio (1592) to Buffon's girl (1749) and the Wart Man of Tilesius (1793): Antique illustrations of mosaicism in neurofibromatosis? *Journal of Medical Genetics*, 40, 227–232.
- Ruggieri, M., Polizzi, A., Marceca, G. P., Catanzaro, S., Praticò, A. D., & di Rocco, C. (2020). Introduction to phacomatoses (neurocutaneous disorders) in childhood. *Child's Nervous System*, 36, 2229–2268. <https://doi.org/10.1007/s00381-020-04758-5>
- Ruggieri, M., & Praticò, A. D. (2015). Mosaic neurocutaneous disorders and their causes. *Seminars in Pediatric Neurology*, 22, 207–233.
- Ruggieri, M., Praticò, A. D., Caltabiano, R., & Polizzi, A. (2018). Early history of the different forms of neurofibromatosis from ancient Egypt to the British Empire and beyond: First descriptions, medical curiosities, misconceptions, landmarks, and the persons behind the syndromes. *American Journal of Medical Genetics - Part A*, 176, 515–550. <https://doi.org/10.1002/ajmg.a.38486>
- Ruggieri, M., Praticò, A. D., Catanzaro, S., Palmucci, S., & Polizzi, A. (2018). Did Cro-Magnon 1 have neurofibromatosis type 2? *The Lancet*, 392, 632–633. [https://doi.org/10.1016/S0140-6736\(18\)31544-7](https://doi.org/10.1016/S0140-6736(18)31544-7)
- Ruggieri, M., Praticò, A. D., & Polizzi, A. C. (2020). Neurocutaneous disorders. In C. di Rocco, D. Pang, & J. T. Ritka (Eds.), *Textbook of pediatric neurosurgery* (pp. 883–917). New York, NY: Springer. https://doi.org/10.1007/978-3-319-72168-2_42
- Ruggieri, M., Praticò, A. D., Scuderi, A., Sorge, G., & Polizzi, A. (2017). The multiple faces of artwork diagnoses. *Lancet Neurology*, 16, 417–418.
- Ruggieri, M., Praticò, A. D., Serra, A., Maiolino, L., Cocuzza, S., Caltabiano, R., & Polizzi, A. (2017). Early history of neurofibromatosis type 2 and related forms: Earliest descriptions of acoustic neuromas, medical curiosities, misconceptions, landmarks, and the pioneers behind the eponyms. *Child's Nervous System*, 33, 549–560.
- Ruggieri, M., Praticò, A. D., Serra, A., Maiolino, L., Cocuzza, S., di Mauro, P., ... Evans, D. G. (2016). Childhood neurofibromatosis type 2 (NF2) and related disorders: From bench to bedside and biologically targeted therapies. *Acta Otorhinolaryngologica Italica*, 36, 345–367.
- Salas-Labadía, C., Gómez-Carmona, S., Cruz-Alcívar, R., Martínez-Anaya, D., del Castillo-Ruiz, V., Durán-McKinster, C., ... Pérez-Vera, P. (2019). Genetic and clinical characterization of 73 pigmentary mosaicism patients: Revealing the genetic basis of clinical manifestations. *Orphanet Journal of Rare Diseases*, 14, 259. <https://doi.org/10.1186/s13023-019-1208-0>
- Selwood, D. (1971). *An introduction to the coinage of Parthia*. London: Spink.
- Simili, R. (2001). *Il Teatro della Natura di Ulisse Aldrovandi*. Bologna: Editrice Compositori.
- Solomon, L. M. (1968). Quasimodo's diagnosis. *The Journal of the American Medical Association*, 204, 190–191.
- Stevenson, J. (2021). *The light of Italy: The life and times of Federico da Montefeltro, Duke of Urbino*. New York, NY: Apollo.
- Sturge, W. A. (1871). Case of partial epilepsy apparently due to lesion of one of vasomotor centres of brain. *Transactions of the Clinical Society of London*, 12, 162–167.
- Tega, W. (2002). Ulisse Aldrovandi museum. In W. Tega (Ed.), *Guide to Palazzo Poggi Museum. Science and art* (pp. 20–25). Editrice Compositori: Bologna.
- Théodoridès, J. (1995). Pierre Francois olive Rayer (1793-1867). *Journal of Medical Biography*, 3, 192–196. <https://doi.org/10.1177/096777209500300402>
- Tilesius von Tilenau, W. G. (1793). *Historia pathologica singularis cutis Turpitudinis: Jo Gondofredi Rheinardi viri Lannorum*. Leipzig: SL Crusius.
- Todman, D. (2008). Warts and the kings of Parthia: An ancient representation of hereditary Neurofibromatosis depicted in coins. *Journal of the History of the Neurosciences*, 17, 141–146.
- Tommasoli, W. (1978). *La Vita di Federico da Montefeltro (1422-1482)*. Urbino: Argalla Editore.
- van Bogaert, L. (1935). Les dysplasies neuroectodermiques congenitales. *Revue Neurologique*, 63, 354–398.
- van der Hoeve, J. (1920). Eye symptoms in tuberous sclerosis of the brain. *Transactions of the Ophthalmology Society*, 20, 329–334.
- van der Hoeve, J. (1921). Augengeschwulst bei der tuberosen hirnsklerose (Bourneville). *Albrecht von Graefes Archiv für Ophthalmologie*, 105, 880–898.
- van der Hoeve, J. (1923). Eye disease in tuberous sclerosis of the brain and in Recklinghausen's disease. *Transactions of the Ophthalmology Society UK*, 45, 534–541.
- van der Hoeve, J. (1932). Eye symptoms in phakomatoses (the Doyle memorial lecture). *Transactions of the Ophthalmology Society*, 52, 380–401.
- van der Hoeve, J. (1933). Les phakomatoses de Bourneville, de Recklinghausen et de von Hippel-Lindau. *Journal of Belge Neurological Psychiatry*, 33, 752–762.
- von Recklinghausen, F. D. (1882). *Über ide multiplen Fibrome der Haut und ihre beziehung zu den multiplen Neuromen* (pp. 3–18). Berlin: Hirschwald.
- Weber, F. P. (1929). A note on the association of extensive haemangiomatic nevus of the skin with cerebral (meningeal) haemangioma, especially case of facial vascular naevus with contralateral hemiplegia. *Proceedings of the Royal Society of Medicine*, 22, 431.
- Widengren, G. (1983). Sources of Parthian and Sasanian history. In E. Yarshater (Ed.), *The Cambridge history of Iran. Volume 3: The Seleucid, Parthian and Sasanid periods, part 2* (pp. 1259–1283). New York, NY: Cambridge University Press.
- Wishart, J. (1822). Cases of tumours in the skull, dura mater and brain. *Edinburgh Medical Surgical Journal*, 18, 393–397.
- Wittkower, R. (1942). Marvels of the east. A study in the history of monsters. *Warburg Courtauld Institution*, 5, 159.
- Yakovlev, P. I., & Guthrie, R. H. (1931). Congenital ectodermoses (neurocutaneous syndromes) in epileptic patients. Bourneville tuberous sclerosis (epiloia). *Archives of Neurology and Psychiatry*, 26, 1145–1194.
- Zanca, A. (1975). Iconografia dermatologica del XVI secolo. Un caso di neurofibromatosi multipla illustrato da Ulisse Aldrovandi. [Dermatological iconography of the XVI century. A case of neurofibromatosis

- illustrated by Ulisse Aldrovandi]. *Archivio Italiano di Dermatologia, Venereologia, e Sessuologia*, 40, 119–123.
- Zanca, A., & Tagliavini, R. (1980). Iconografia dermatologica e venereologica: ieri e oggi. *Acta Medicae Historiae Patavina*, 27, 81–97.
- Zanca, A., & Zanca, A. (1977). Iconografia dermatologica del passato. Antiche illustrazioni di neurofibromatosi multipla. *Chronica Dermatologica*, 2, 283–287.
- Zanca, A., & Zanca, A. (1980). Antique illustrations of neurofibromatosis. *International Journal of Dermatology*, 9, 55–58.

How to cite this article: Ruggieri, M., Gentile, A. E., Ferrara, V., Papi, M., Praticò, A. D., Mudry, A., Taruscio, D., Micali, G., & Polizzi, A. (2021). Neurocutaneous syndromes in art and antiquities. *American Journal of Medical Genetics Part C: Seminars in Medical Genetics Part C*, 187C:224–234. <https://doi.org/10.1002/ajmg.c.31917>